

Case Report

# Stroke In Young, Hyperhomocysteine and Associated With COVID-19 Illness- A Case Report

Sagar Gupta

DNB Medicine, Fellowship in Critical care medicine, Consultant Physician & Intensivist, Department of Medicine Dr Hedgewar Hospital, Aurangabad, Maharashtra, India.

DOI: <https://doi.org/10.24321/2349.7181.202020>

## I N F O

**E-mail Id:**

sargargupta2303@gmail.com

**Orcid Id:**

<https://orcid.org/0000-0002-9378-1701>

**How to cite this article:**

Gupta S. Stroke In Young, Hyperhomocysteine and Associated With COVID-19 Illness- A Case Report. *J Adv Res Med* 2020; 7(4): 20-23.

Date of Submission: 2021-02-19

Date of Acceptance: 2021-03-01

## A B S T R A C T

As COVID-19 patients are at high risk of thrombotic complications this makes physician aware of close monitoring of both neurological status and cardiovascular status. Along with involvement of respiratory system, pathological process carries both inflammation and hyper coagulopathy both simultaneously. Homocystein as high risk predictor of stroke in young which is unmasked due to hypercoagulable state of COVID-19.

**Keywords:** Stroke in Young, SARS IGG Antibody, Post COVID-19 Sequel, Hyperhomocysteine, Post COVID Thrombotic Complications

## Introduction

Homocysteine is a sulfur containing amino acid i.e. generated during methionine metabolism it has a physiological role in DNA metabolism via methylation a process govern by the presentation of folate and vitamin B6 & B12. Elevated plasma levels of homocysteine can be caused by deficiency of either vitamin B12 or folate or a combination there. Certain genetic factors also cause elevated homocysteine such as C667T substitution of the gene coding methylenetetrahydrofolate reductase. Elevated homocysteine has been observed in several medical conditions such as cardiovascular disorders, orthosclerosis, myocardial infarction, stroke, and minimal cognitive impairment, dementia, Parkinson 's disease, multiple sclerosis, epilepsy and eclampsia. Elevated homocysteine, extract direct toxic effects on both vascular and nervous system.

Diet abundant in vegetables, fruits, and can reserve in reduction in plasma level of homocysteine.<sup>1</sup> Polymorphism of the C667T genotype of gene encoding MTHFR generally

plays a minor role in determining homocysteine levels in healthy individuals.

## Elevated Homocysteine and Stroke

Cerebrovascular stroke is one of the major cause of morbidity worldwide. Prospective and retrospective clinical studies have shown that elevated homocysteine is a high risk marker of stroke and one of the causes of stroke in young.<sup>2</sup> As we found thrombotic episodes of cerebral vasculature is associated with thrombo-inflammation of COVID-19 illness, here there is incidental detected high homocystein along with that. The magnitude of plasma homocysteine elevation was observed to be associated with a graded increase in the pulsatility index (which is major of the increased vascular resistance in artery). An homocysteine greater than 14.0 nmol/ L is significantly associated with the progression of cerebro vascular event that is occlusion, which is an independent risk factor for recurrent vascular event in transient ischemic attack and cerebrovascular stroke in young. Daily supplemental multivitamins with folate at 400

to 1000 ug, B12 at 400-600 ug, B6 at 2-10 mg have been suggested as primary prophylaxis for the individuals with known cerebro vascular disease and elevated homocysteine.

### Case History

28 yr old male patient presented at 6 pm to emergency room at Dr Hedgewar Hospital with no any previous history of medical illness, ambulatory job profile, with sudden onset of light headedness and fall at 12 pm noon on same day and sudden onset disorientation and weakness of right upper & lower limb with facial deviation, since 4 pm evening on same day. He denies any history of tobacco or alcohol consumption with no family history of DM, HTN, IHD, any CNS illness. O/e his vitals were HR: 86/min regular on both radials, all pulsations normal, BP: 150/80 mmhg, CVS & RS examination were completely normal, CNS examinations: Mild disorientation (drowsyness), complete loss of power of right UL & LL (0/5), he gradually regained complete

sensorium after 72 hrs with residual right UL & LL weakness with power of (3/5), on suspicion of reason for stroke in young homocystein measured which found high as a high risk predictor of stroke in young.

MRI S/o Large acute infarct in left gangliocapsular region. Left insular cortex, frontal lobe, and few similar areas in left temporal and parital lobe, with hemorrhagic transformation noted in left caudate and lentiform nucleus. Small chronic infarct in left frontal lobe.

MR angiography reveals M1 segment of left MCA appears normal with mild narrowing of M2 segment and paucity of cortical branches of left MCA likely s/o Thrombosis.

1. 12 lead ECG: Normal study.
2. 2 D Echo: Normal LV function, LVEF 66%, No RWMA, size and morphology of valves & chambers normal, No clot or vegetation.
3. Chest X-ray: Done on admission, Within normal limits.

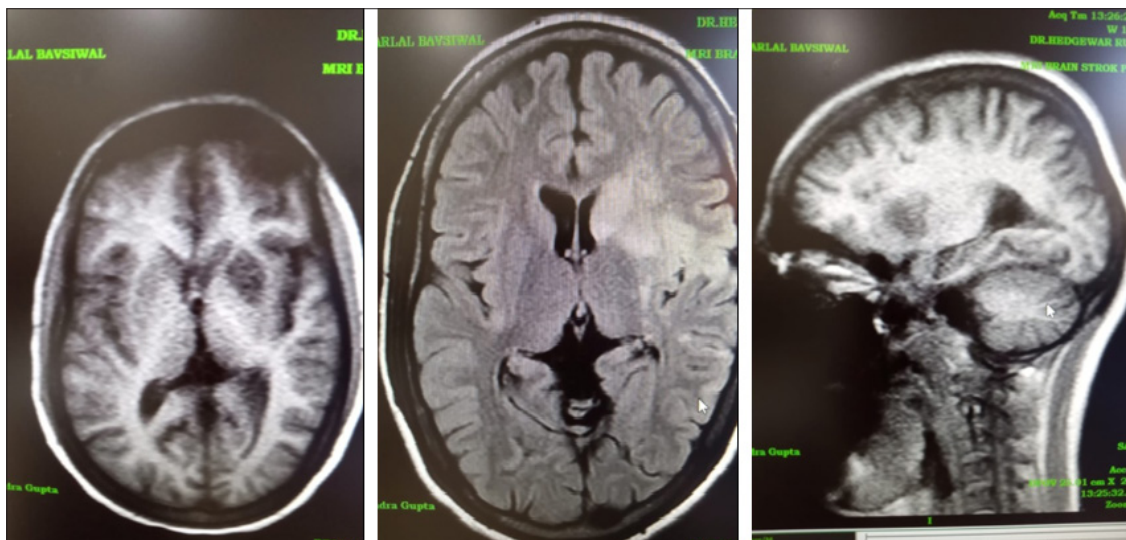


Figure 1. MRI images suggestive of Infarct

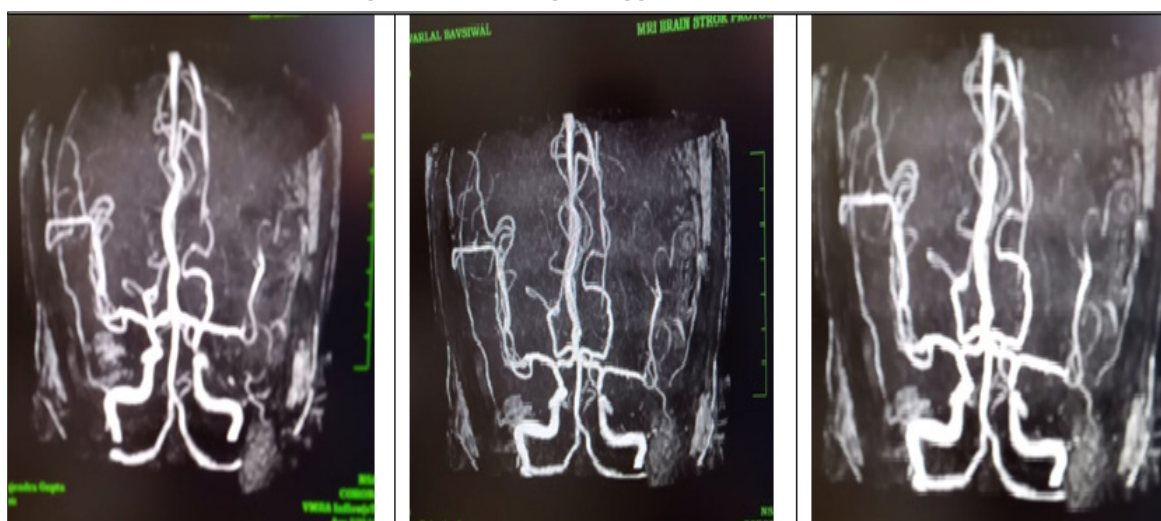
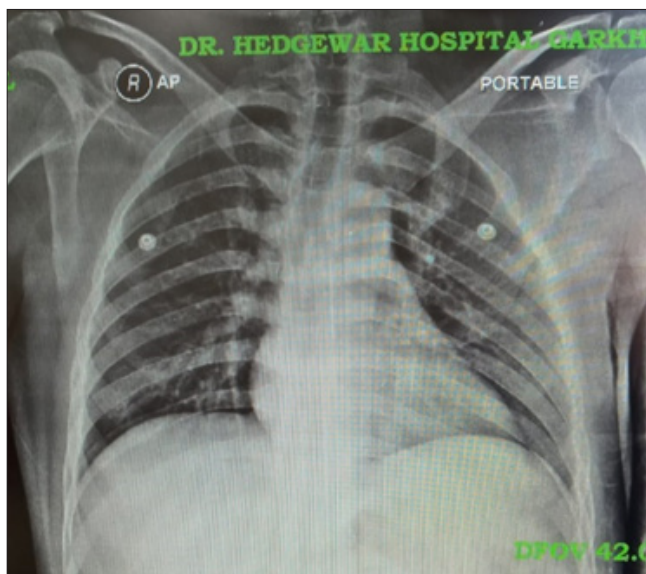


Figure 2. MR Angiogram



**Figure 3. Chest radiogram**

On further evaluation he did not give any history of any viral illness symptoms considering current pandemic of COVID-19, but on retrospective evaluation his COVID / SARS COV IgG antibody reactive with significant raised titer suggesting that he might have asymptomatic covid infection in recent 2- 4 weeks, his homocysten level were high as he was case of stroke in young.

### Investigations

| Name                           | Observed value   | Reference range |
|--------------------------------|------------------|-----------------|
| IgG SARS Cov-2 Antibody (CLIA) | : Reactive 16.50 | < 1.0           |
| Urea                           | : 20.4           | 17-40           |
| Creatinine                     | : 0.56           | 0.72-1.18       |
| Na+                            | : 137 meq/L      | 135-148         |
| K+                             | : 4.12 meq/L     | 3.5-4.5         |
| TSH                            | : 1.29 MIV/ml    | 0.35 - 4.94     |
| Hb                             | : 10.0           | 13.0 – 17.0     |
| TLC                            | : 9000           | 4000-10000      |
| Neutrophil                     | : 69.1 %         | 40-80 %         |
| Lymphocyte                     | : 22.4 %         | 20-40 %         |
| Platelets                      | : 168000         | 150000 - 410000 |
| Prothrombin time               | : 17.2           | 11-16           |
| Homocysteine                   | : 50 umol/L      | 5.46 - 16.2     |

### Discussion

As we know COVID-19 infection is coming with typical and atypical presentations to emergency department.

Thrombotic complications are secondary to hypercoagulable state and pro-inflammatory state secondary to COVID-19, this patient never gave history of fever, cough, or symptoms of respiratory illness and presented with cerebrovascular stroke as a initial presentation. On the background of current COVID pandemic on retrospective screening he was detected IgG COVID antibody reactive suggesting that acquired recent past COVID-19 disease which was asymptomatic. In recent days with active COVID infection we noted many cases with cardiovascular and cerebrovascular events,<sup>3</sup> DVT, pulmonary embolism, superior mesenteric artery thrombosis, renal artery thrombosis as initial presentation with simultaneous COVID-19 infection and in few cases with asymptomatic COVID-19 infection proved by IgG antibody reactive on retrospective evaluation.

This makes physicians or intensivists alert to suspect screening for COVID-19 illness in any vascular events specifically with comorbidities like DM, HTN, IgG antibody becomes an excellent tool in such clinical scenarios of cases with vascular events. In our case elevated homocysteine level probably have unmasked cerebrovascular events,<sup>2</sup> as it is high risk factor to cause thrombotic complications.<sup>4</sup>

Hypercoagulable state in COVID-19 is emerging major pathological occurrence with serious consequences in mortality and morbidity. It is clear that this derangement in hemostatic pathways is unlike the one seen in other kinds and infection, sepsis, or ARDS. Some anticoagulation may not be sufficient, hypercoagulability of SARS CoV 2 infection, a unique mechanism of thrombo inflammation triggered by viral infection originating in pulmonary vasculature. Identification of biomarkers of thrombosis and severe illness can guide clinicians.

### Conclusion

During COVID-19 pandemic it is need of time to closely observe cerebrovascular and cardiovascular events and related pathologies while treating patient. It has become again more importance to track history of COVID illness in past.

In this article we have highlighted stroke in young adult following COVID illness, there are more probable chances to develop coagulopathy, changes in homocysteine level and may cause development of cerebrovascular event in young adults.

**Conflict of Interest:** None

### References

1. Ponti G, Ruini C, Tomasi A. Homocystein as potential predictor as cardiovascular risk in patient with COVID 19. *Med Hypotheses* 2020; 143:109859. DOI: 10.1016/j.mehy.2020.109859.

2. Ansari R, Mahta A, Mallack E et al. Hyperhomocysteinemia and Neurologic Disorders: a Review. *Journal of Clinical Neurology* 10(4): 281.
3. Aboo-ismail MY, Diamond A, Kapoor S et al. The hypercoagulable state in COVID 19 incidence, pathophysiology and management. *Thrombosis Research* Vol 194: 101-115. <https://doi.org/10.1016/j.thromres.2020.06.029>.
4. Oxley TJ, Mocco J, Majidi S et al. Large-Vessel Stroke as a Presenting Feature of Covid-19 in the Young | NEJM. (2021). NEJM. Retrieved from <https://www.nejm.org/doi/full/10.1056/NEJMc2009787>