

Case Report

# Idiopathic Intracranial Hypertension with Multiple Cranial Nerve Involvement: A Clinical Enigma

Ankita Sheoran<sup>1</sup>, Renu Dabas<sup>2</sup>, Ayush Malhotra<sup>3</sup>, Pratap Singh<sup>4</sup>

<sup>1</sup>Postgraduate Resident, <sup>2,3</sup>Senior Resident, <sup>4</sup>Associate Professor, Department of Medicine, Dr. RML Hospital, New Delhi, India.  
DOI: <https://doi.org/10.24321/2349.7181.201910>

## I N F O

### Corresponding Author:

Pratap Singh, Department of Medicine, Dr. RML Hospital, New Delhi, India.

### E-mail Id:

[drpratapsingh@yahoo.co.in](mailto:drpratapsingh@yahoo.co.in)

### Orcid Id:

<https://orcid.org/0000-0001-6291-4287>

### How to cite this article:

Sheoran A, Dabas R, Malhotra A et al. Idiopathic Intracranial Hypertension with Multiple Cranial Nerve Involvement: A Clinical Enigma. *J Adv Res Med* 2019; 6(2): 20-22.

Date of Submission: 2019-08-25

Date of Acceptance: 2019-09-09

## A B S T R A C T

Idiopathic Intracranial Hypertension (IIH), previously known as Pseudotumor cerebri is characterized by raised intracranial pressure without any obvious reason. Early clinical suspicion and targeted investigations are crucial for early diagnosis and can prevent potential blindness. We hereby report this case of a young lady who presented with involvement of multiple cranial nerves, and responded dramatically to the treatment.

**Keywords:** Cranial Nerve, CSF, IIH

## Introduction

Idiopathic Intracranial Hypertension (IIH) is classically a disease of obese women of childbearing age, however age is no bar to presentation. It is characterized by clinical symptoms of raised intracranial pressure, elevated CSF opening pressure on lumbar puncture, normal CSF studies and usually normal imaging studies. The disease is thought to result from decreased absorption of CSF from arachnoid villi, and sometimes increased CSF production due to venous congestion resulting from restricted venous drainage.<sup>1</sup> Early diagnosis and treatment prevent the vision loss.

## Case Presentation

A 35-year-old lady with no prior comorbidities presented to medical outpatient department with complaints of headache for six months, nausea and vomiting for three months, diplopia for two months and drooping of right

eyelid for one and half months. There was no history of seizures, altered mentation, fever, head trauma, falls or gait instability. She did not have weakness in any of her limbs, any sensory complaints or bowel and bladder disturbances. No history of tuberculosis or any other chronic illnesses in past was there. Her menstrual cycles were normal. She had two live healthy children (with last child birth 10 years back) without any significant obstetric history. However, patient had history of regular oral contraceptive use for past 9 years. She also told that she had an unintentional weight gain of 12 kilograms over past 1 year. There was no history suggestive of autoimmune disorders like lupus, Behcet's disease, sarcoidosis or endocrinopathies or any other chronic drug intake except contraceptive pills.

On clinical examination, she was conscious, well oriented and had stable vital parameters. Her height was 152 cm and weight were 69 kg (BMI-29.86 kg/m<sup>2</sup>). There was no

pallor, cyanosis, clubbing, lymphadenopathy or thyroid enlargement. On central nervous system examination, she had normal higher mental functions, motor and sensory systems including cortical sensations, normal reflexes and normal cerebellar functions. However, on examining cranial nerves, we found involvement of I<sup>st</sup>, II<sup>nd</sup>, III<sup>rd</sup>, IV<sup>th</sup> and VI<sup>th</sup> cranial nerves. She had bilateral impaired olfaction. Her visual acuity was reduced for near as well as far vision (right eye-6/12, left eye-6/9), decreased perception of colors which she described as dullness of colors, bilaterally impaired visual fields, impaired direct and consensual light reflex in right eye and impaired consensual reflex in left eye. Fundus examination revealed pale disc with blurred margins in right eye and hyperemic disc with blurred margins in left eye. On examining III<sup>rd</sup>, IV<sup>th</sup> and VI<sup>th</sup>, there was bilateral ptosis(right>left), mid dilated right pupil, proptosis in right eye and bilateral lateral rectus palsy. Rest of the cranial nerves were essentially normal on clinical examination.

In the face of her symptoms suggestive of raised intracranial pressure and involvement of bilateral multiple cranial nerves and papilledema on examination, possibilities of cavernous sinus thrombosis, Dural sinus thrombosis, intracranial space occupying lesion, idiopathic cavernous sinusitis and idiopathic intracranial hypertension were considered and she was worked up further.

On investigation, she had normal blood counts, liver and kidney function tests, blood glucose and serum electrolytes. Her chest roentgenogram and electrocardiograph did not reveal any abnormality. Her hormonal profile including thyroid function tests, parathormone and vitamin D levels were also normal. Other tests including those for antinuclear antibodies, antiphospholipid antibodies were negative. Automated perimetry was performed to confirm visual field defects, which showed bilaterally impaired fields of vision (Figure 1) Gadolinium enhanced MRI brain with venography was done which revealed partial empty sella and hypoplastic left transverse sinus (Figure 2). Guarded lumbar puncture was done, CSF opening pressure was raised (>300 mm H<sub>2</sub>O in lateral decubitus) and CSF analysis was normal.

Considering the clinical presentation, risk factors of being obese, female gender, history of OCP intake, and imaging findings, final diagnosis of idiopathic intracranial hypertension/pseudotumor cerebri was made as per the diagnostic criteria of Pseudotumor Cerebri by Friedman. She was then treated with cerebral decongestants (acetazolamide, furosemide, mannitol) and topiramate. During her hospitalization, her symptoms like headache, vomiting and ptosis improved significantly but diplopia was improved minimally.

She was discharged on acetazolamide and topiramate and advised for weight reduction strategies. During follow up visits, she had significant improvement with all her

symptoms resolved except diplopia for far-vision after 4 months of regular treatment.

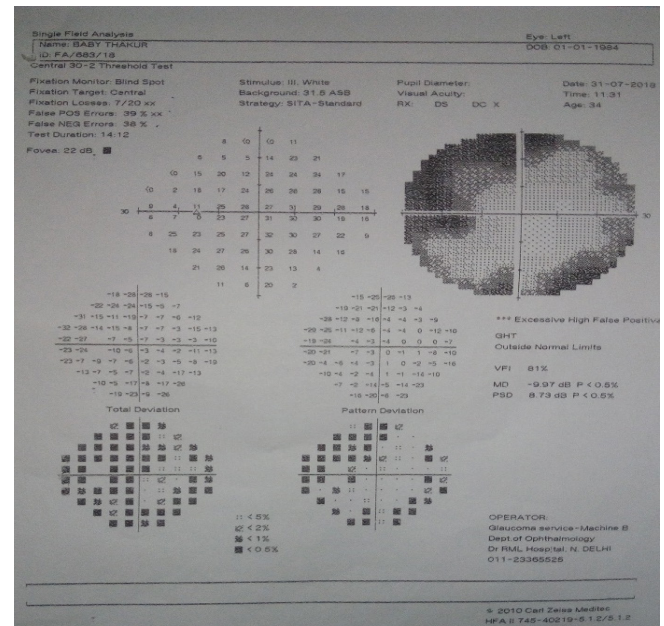


Figure 1. Automated perimetry

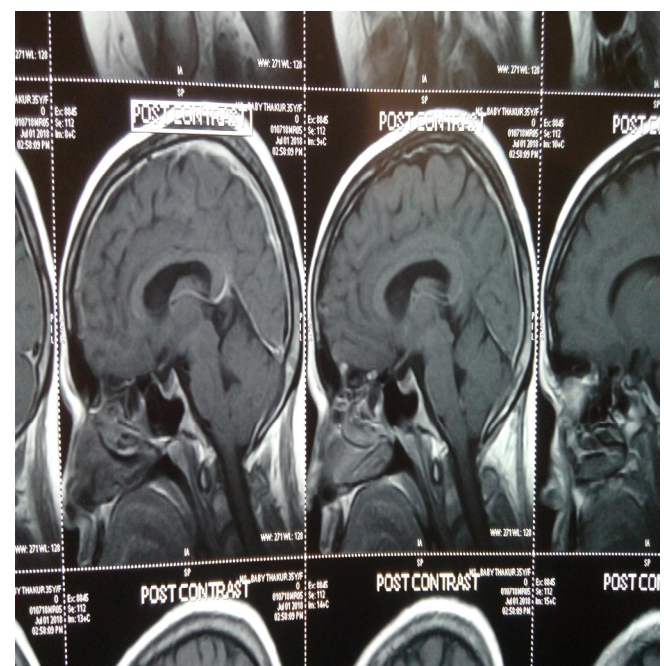


Figure 2. CEMRI brain showing partially empty sella

## Discussion

Idiopathic intracranial hypertension, also known as Pseudotumor cerebri, is a disease of obese women of childbearing age, however cases have been reported in children and adult males also.<sup>2</sup> Reported incidence is 1-2 in 100,000 in general population and up to 4-21 cases per 100,000 in obese young women).<sup>2</sup> The disease is believed to occur due to decreased absorption of CSF

from arachnoid villi and less commonly due to increased CSF production. Traditional risk factors associated with IIH include obesity, female gender, certain drugs (growth hormone, tetracyclines (outdated), hypervitaminosis A, oral contraceptive pills, lithium, nitrofurantoin, phenytoin, tamoxifen), endocrinopathies (Addison's disease, PCOS, hypoparathyroidism) and rarely- Behcets disease, lupus, Lyme's disease, long standing anemia, leukemias and Dural venous sinus thrombosis.<sup>3</sup>

Classical symptoms include retroorbital headache which worsens with eye movements, pulsatile tinnitus, nausea, vomiting, dizziness, visual obscurations/ amaurosis, photopsia, diplopia and neck pain.

#### Friedman's Diagnostic Criteria for Pseudotumor Cerebri<sup>4</sup>

- Papilledema
- Normal neurological examination except cranial nerve abnormalities
- Neuroimaging: normal brain parenchyma, no hydrocephalus/ space occupying lesion/ meningeal enhancement
- Normal CSF composition
- Elevated CSF opening pressure (>250 mm in adults, >280 in children)

Definite IIH is when all the criteria(A-E) are met. It is 'Probable IIH' when criteria A-D are present but CSF pressure is lower than specified.

Ophthalmologic evaluation should include fundoscopy, perimetry and Optical Coherence Tomography (OCT) which aid in early diagnosis. Neuroimaging with magnetic resonance imaging may reveal flattening of globe of eyeball, empty sella, enlarged optic nerve sheath with tortuosity of nerve and protrusion and enhancement of optic nerve head, and sinovenous stenosis on venography.<sup>5</sup>

Treatment is aimed at preserving vision and reducing symptoms. Medical treatment includes acetazolamide, loop diuretics (furosemide) and topiramate. Topiramate is effective due to its weak carbonic anhydrase inhibitory activity, anti-migraine effect and suppression of appetite which promotes weight loss.<sup>6</sup> Experimental therapies include octreotide and somatostatin analogues. For fulminant disease, corticosteroids can be used to reduce ICP acutely till surgery, but risk of weight gain and fluid retention remains a concern on long term use. There is a controversy whether stenting or shunting is the optimal treatment for TSS in IIH. In our opinion, it is reasonable to initiate treatment with CSF diversion. For worsening symptoms or resistant cases or malignant/ fulminant IIH, optic nerve sheath decompression or fenestration, ventriculoperitoneal/ ventriculoatrial/ lumboperitoneal shunt can be considered. Transverse sinus stenting is an emerging surgical option

with proven results.<sup>7</sup> Weight reduction remains elemental in all the management strategies.

#### Conclusion

We have brought up this case to sensitize physicians to this potentially blinding disease especially in young women if there is delay in diagnosis. Involvement of cranial nerves other than optic nerve is rare but reported. CSF analysis was normal except raised opening pressure. However, diagnosis remains that of exclusion, once other causes are being ruled out. Timely diagnosis and treatment are essential to prevent the vision loss.

**Consent:** written consent was taken from patient along with approval from Institutional Ethical Committee (IEC) for publication.

**Financial Aid:** None

**Conflict of Interest:** None

#### References

1. Boulton M, Armstrong D, Flessner M et al. Raised intracranial pressure increases CSF drainage through arachnoid villi and extracranial lymphatics. *Am J Physiol* 1998; 275(3Pt2): 889-896.
2. Lee A, Wall M. Idiopathic intracranial hypertension (pseudotumor cerebri): epidemiology and pathogenesis. Available from: <http://www.uptodate.com/contents/idiopathic-intracranial-hypertension-pseudotumor-cerebri-epidemiology-and-pathogenesis>. Accessed January 22, 2019.
3. Chen J, Wall M. Epidemiology and Risk Factors for Idiopathic Intracranial Hypertension. *Int Ophthalmol Clin* 2014; 54(1): 1-11.
4. Friedman DI, Liu GT, Digre KB. Revised diagnostic criteria for the pseudotumor cerebri syndrome in adults and children. *Neurology* 2013; 81(13): 1159-1165.
5. Degnan AJ, Levy LM. Pseudotumor cerebri: brief review of clinical syndrome and imaging findings. *American Journal of Neuroradiology* 2011; 32(11): 1986-1993.
6. Celebisoy N, Gokcay F, Sirin H et al. Treatment of idiopathic intracranial hypertension: topiramate vs acetazolamide, an open-label study. *Acta Neurol Scand* 2007; 116: 322-327.
7. Kanagalingam S, Subramanian P. Cerebral venous sinus stenting for pseudotumor cerebri: a review. *Saudi J Ophthalmol* 2015; 29(1): 3-8.