



Research Article

A Rare Case of Pulmonary Thromboembolism and Acute Respiratory Distress Syndrome (ARDS) in Scrub Typhus

Chevuri Mounika¹, Gadiraju Durga Praneetha¹, Durga Krishnan², Kaliyannan Mayilanthi²,
Vrinda Vijayakumari³

¹Postgraduate Resident, ²Professor, ³Assistant Professor, Department of General Medicine, Chettinad Hospital and Research Institute, Chettinad Academy of Research and Education, Kelambakkam, Kancheepuram, Tamil Nadu, India.

DOI: <https://doi.org/10.24321/0019.5138.202247>

I N F O

Corresponding Author:

Gadiraju Durga Praneetha, Department of General Medicine, Chettinad Hospital and Research Institute, Chettinad Academy of Research and Education, Kelambakkam, Kancheepuram, Tamil Nadu, India.

E-mail Id:

praneethagadiraju9993@gmail.com

Orcid Id:

<https://orcid.org/0000-0002-2197-6542>

How to cite this article:

Mounika C, Praneetha GD, Krishnan D, Mayilanthi K, Vijayakumari V. A Rare Case of Pulmonary Thromboembolism and Acute Respiratory Distress Syndrome (ARDS) in Scrub Typhus. *J Commun Dis.* 2022;54(1):36-40.

Date of Submission: 2021-10-30

Date of Acceptance: 2022-02-15

A B S T R A C T

Orientia tsutsugamushi causes scrub typhus, a zoonotic illness (*O. tsutsugamushi*). The disease is spread to humans through the biting of trombiculid mite larvae (chiggers). The case report adds light to thrombus formation in scrub typhus infection, an often-under-diagnosed entity. We report a 17-year-old female who presented with complaints of breathlessness after 11 days of symptoms of fever. The condition is widespread in India, with cases reported in a number of states. Persons are infected by the larval development (chigger) of trombiculid mites. Chiggers are spread by wild rats, and illness develops when chiggers feed on humans.

Laboratory investigations revealed leukocytosis, thrombocytopenia, and radiological investigations showed ARDS and pleural effusion, and the patient was diagnosed to have scrub typhus. Treatment was given for the infection and its complications.

Keywords: Scrub Typhus, Thrombocytopenia, ARDS, Pleural Effusion

Introduction

Orientia tsutsugamushi causes scrub typhus, a zoonotic illness (*O. tsutsugamushi*). Trombiculid mite larvae bite humans, transmitting the disease (chiggers). It's a re-emerging infectious disease in India. Some of the clinical signs include high-grade fever, headache, weight loss, muscle aches, eschar, lymphadenopathy, and a maculopapular rash. Problems occur from the first week of illness in case of scrub typhus. The consequences include meningoencephalitis, liver disease, myocarditis, ARDS, and kidney disease. Eschar

and rash can go unnoticed or may altogether disappear. Scrub typhus can be diagnosed, treated, and prevented with a comprehensive medical examination and the discovery of eschar/ rash. In this publication, we provide a case study of scrub typhus in a critical care unit with pulmonary embolism seen with acute respiratory distress syndrome.

Case Report

A 17-year-old female came to the emergency department of Chettinad Hospital and Research Institute, Chennai, India, with complaints of high-grade fever with chills and rigors



for 11 days, headache and myalgia for 10 days, and dry cough for 3 days and breathlessness since 2 days. There was no substantial medical, surgical, or family history of sickness in the past. She discontinued her studies and stayed with her brother in Chennai. She had 2 pet dogs at her residence. She had been admitted to a medical centre for in-patient therapy for five days before present admission, where she was empirically treated for malaria and started on artemether and a few other antibiotics, but there was no improvement. Because of persistent fever, cough and breathlessness, she was brought to our hospital.

On day 1 of her admission, the patient complained of high-grade fever, shivering, cough, breathing difficulty, headache, and generalised weakness. She was conscious, pale, her pulse rate was 134 beats per min and regular in rhythm, respiratory rate was 36 breaths per min, blood pressure was 90/60 mmHg in the right upper arm in supine position and temperature was 102°F, SPO₂ was 84% in room air and 96% with 4 litres of oxygen supplementation via face mask. She had a non-blanching rash over the bilateral lower limb and an eschar was found in the right axilla on a thorough general examination which gave us the clue for scrub typhus (Figure 1). On examination of the respiratory system, findings were bilaterally reduced breath sounds and bilateral basal crepitations. The results of the other systems examinations were all normal.

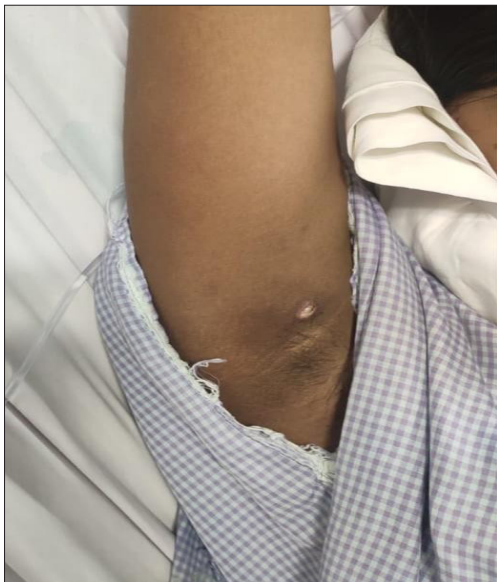

Figure 1. Eschar on Right Axilla

A chest radiograph PA view showed bilateral pleural effusion and radio-opacities in bilateral middle, and lower zones of right and left lungs, as seen in Figure 2. Her trans-thoracic echocardiography evaluation was normal. Computerised tomography image of the chest was taken, which showed patchy areas of nodular ground-glass opacities and consolidation involving all lobes of both lungs, and diffuse

areas of smooth interlobular septal thickening in bilateral lungs predominantly in upper lobes (Figure 3). Features suggestive of acute respiratory distress syndrome, acute interstitial oedema, and bilateral mild to moderate pleural effusion were noted. She was initially on face mask, then she had a drop in saturation slowly and gradually by evening, so she was shifted to ICU, and 2 days after admission to ICU, she developed desaturation and was started on non-invasive mechanical ventilation. Arterial Blood Gas (ABG) analysis revealed (pO₂-38.6) type I respiratory failure.

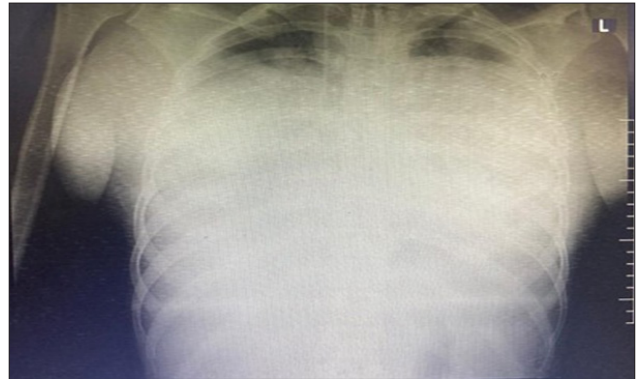


Figure 2. PA View of Chest X-Ray showing Bilateral Pleural Effusion

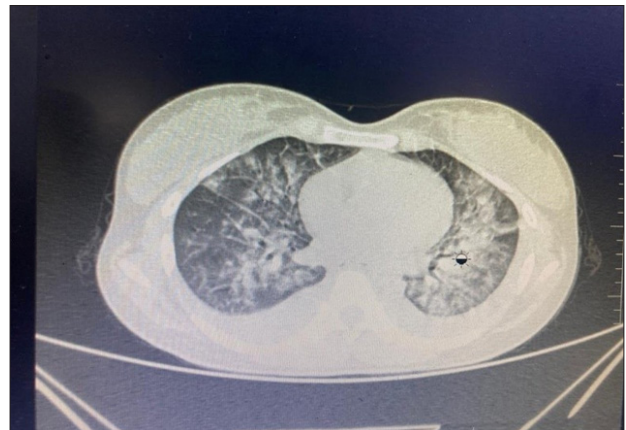

Figure 3. Computerised Tomography Chest showing Features of ARDS

Blood was sent for investigations - procalcitonin (3.45), D-dimer (5228), LDH (489), CRP (107), ferritin (369.5), IL-6 (65.16), and all cultures were sent.

Empirical antibiotic treatment was started with intravenous meropenem and doxycycline. Laboratory data revealed leucocytosis (12,000), thrombocytopenia (57,000), elevated aspartate aminotransferase, alanine aminotransferase, and hypoalbuminemia. Scrub typhus Ig MELISA sample was sent. Smears for malaria parasite turned out to be negative. Widal test, Leptospira, and dengue serology were negative. Blood, urine, and sputum samples were sterile. Her scrub IGM serology turned out to be positive as expected.

In view of tachypnoea and further deterioration of the patient's respiratory signs and symptoms, the patient was electively intubated on day 2, yet the patient continued to have fever spikes, so she was started on inj. azithromycin intravenously on day 3 of admission.

The patient was on mechanical ventilation for 7 days, and 5 cycles of proning and deproning ventilation were given. She was started initially on a prophylactic dose of inj. Clexane subcutaneously for deep vein thrombosis. While on ventilator, a repeat chest X-ray showed progressively increasing pleural effusion left more than right, for which tapping had been done and pleural fluid was sent for all routine investigations.

Pleural fluid report suggestive of exudative fluid (turbid, straw-coloured, 200 cells/cumm, lymphocyte-pre dominant-72% -reactive effusion, glucose-104, protein-3.0, albumin-1.5, LDH-476). No growth was found in pleural fluid.

After extubation, the patient maintained saturation without oxygen support. Chest physiotherapy and incentive spirometry were encouraged on a regular basis every day, but the patient continued to have persistent tachypnoea. Her serial X-rays were improving, but on day 2, after extubation, X-ray chest showed a wedge-shaped opacity in the right lower lobe of the lung (Figure 4). We suspected thrombus formation in the pulmonary artery, so we proceeded with computed tomographic pulmonary angiography, which showed an intra-luminal partial thrombus in the lobar segment of pulmonary artery on the lower lobe of right side. Therapeutic dosage of inj. Clexane twice daily, subcutaneously for 5 days was started in view of pulmonary thromboembolism, which is a rare haematological complication in scrub typhus infection. The patient symptomatically improved, and hence was discharged. She came for follow up after 2 weeks. She had no complaints and had symptomatically improved. Chest X-ray PA view was repeated which showed significant improvement in bilateral lung fields (Figure 5).

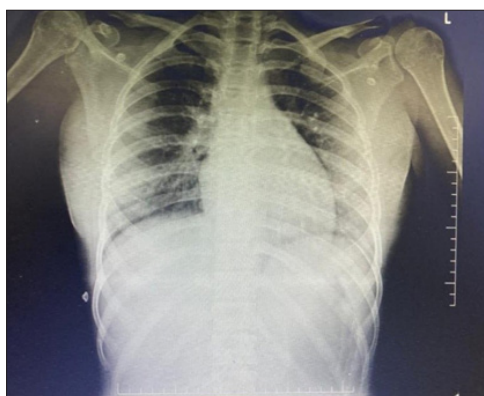

Figure 4.AP View of X-Ray showing Wedge-shaped Opacity on Right Side

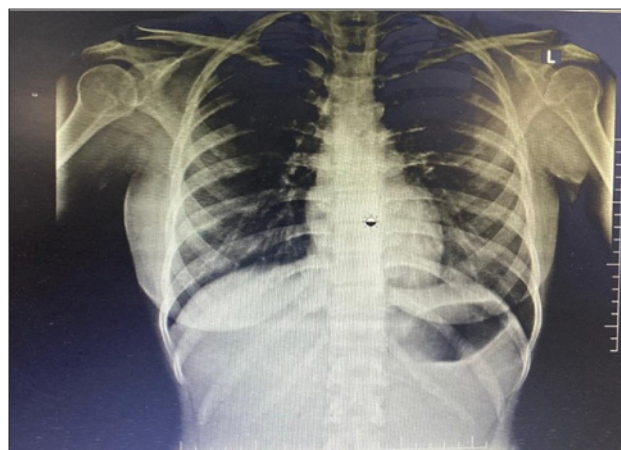

Figure 5.PA View of X-Ray after Discharge during Follow up

Discussion

The gram-negative bacterium *Orientia tsutsugamushi* causes scrub typhus, an acute fever disease (family Rickettsiaceae). It is only found in the "Tsutsugamushi triangle", a region of the world where it is endemic. The condition is widespread in India, with cases reported in a number of states. Humans are infected by the larval stage (chigger) of trombiculid mites. Chiggers are spread by wild rats, and infection develops when chiggers feed on humans. According to the literature, persons who live in rural areas, agricultural workers, and soldiers are more likely to be exposed.^{1,2}

The main symptoms of this illness range from fever (83.3%), headache, non-productive cough, myalgia (76.9%), maculopapular rash (46.2%), and eschar (66.7%) to life-threatening complications such as lung inflammation, encephalitis, and peripheral cardio vascular failure. An effective diagnostic feature is a necrotic eschar just at the wound surface, a hint of typhus eradication.³ Our patient also had eschar but before presenting to our hospital, eschar was scrapped by the patient. Due to wider manifestations, infection tends to be underdiagnosed or wrongly diagnosed. Diagnosis is usually made with scrub IGM ELISA having a sensitivity of 86.5%, which also turned out to be positive in our patient.^{4,5}

Acute respiratory distress syndrome (ARDS) is an uncommon but significant consequence of scrub typhus that includes acute dyspnoea with fast onset, hypoxemia, and widespread lung infiltrates leading to respiratory failure. Symptomatic emergence of extreme hypoxemia with a magnitude relation of arterial pO_2 to inspired oxygen fraction (PaO_2/FiO_2) of less than 100 mmHg,⁶ bilateral opacities coherent with oedema not properly described by pleural effusion, lobar/lung collapse, or nodules on chest radiograph have all been recognised standards for ARDS. At the time of presentation, thrombocytopenia was noted as platelet count was less than 150000/mm³.⁷ Identification of inflammatory

reaction on a chest radiograph at least 2 days prior to the beginning of ARDS was considered preclinical reactive airway.⁸ All the above criteria were met in our patient. Pulmonary manifestations vary from bronchitis to interstitial pneumonitis progressing to ARDS.⁹ The average age was 43 years, with the age ranging from 21 to 65 years of age.¹⁰ We present you a case of a female who was 17 years of age, and was presented lately with acute respiratory distress syndrome features, thrombocytopenia, and lung opacities manifested due to scrub typhus.

Wang CC et al. stated that there are around 11% of scrub typhus cases developed due to ARDS. The death rate was roughly 25%, and prompt treatment with antimicrobial therapy helped to reduce it.¹¹

Scrub typhus accounted for more than 15% of cases brought to ICU with a presumptive description of tropical infections, according to statistics provided at the Indian Society of Critical Care Medicine's (ISCCM) annual gathering in 2014. Ventilation system was necessary for 37% of scrub typhus individuals with hypoxemia, while non-invasive ventilation was indicated in 15.55%.¹² Encephalopathy was an independently associated cause of death. Our patient was infected with scrub typhus, and her malaria parasite test turned out to be negative.

The peculiar finding, in this case, is partial thrombus in the pulmonary artery. The key pathogenic mechanism is *O. tsutsugamushi*'s development in capillary endothelium membranes; injury to vascular endothelial cells promotes perivascular immune activation, endothelium growth, and microvascular thrombus formation.¹³ Interstitial infection and parietal effusion may be caused by a change in the proportion between the hydrostatic and oncotic factors favouring dynamic absorption into the pulmonary. The link between endothelial cell destruction and systemic immune response has been linked to the pathophysiology of scrub typhus illness, according to investigators. In scrub typhus patients, clotting and systemic inflammation were elevated, where as anti-coagulant factors were repressed.¹⁴

Conclusion

We present to you a 17-year-old female, who came to our hospital with ARDS clinical presentation, treated as malaria outside, and we think that delayed treatment would have been the cause of severity in this case. This is our first case of scrub with ARDS and partial thrombus in right pulmonary artery presentation in our hospital. This is our endeavour to emphasise the importance of a complete history, clinical examination, and understanding of scrub typhus symptoms such as ARDS, renal failure, thrombosis, and occasionally multi-organ dysfunction. Scrub typhus has great clinical potential in tropical countries. The lack of any rash or traditional eschar, or the appearance of eschar on hidden

regions of the body, such as the scrotum or axilla, increases the likelihood of a missed diagnosis. The specificity for the diagnosis of scrub typhus may increase if a combination of increased serum transaminase, thrombocytopenia, and leukocytosis is employed.

Acknowledgement

I would like to extend my heartfelt gratitude to Prof Dr Durga Krishnan, Prof Dr Mayilananthi, and Dr Vrinda V, Assistant Professor, General Medicine Department, Chettinad Hospital and Research Institute. I would also like to thank the Department of General Medicine of Chettinad Hospital and Research Institute for their constant support.

Conflicts of Interest: None

Sources of Funding: None

References

1. Hornick RB. Rickettsial diseases. In: Bennett JC, Plum F, editors. Goldman: Cecil textbook of medicine. 21st ed. Philadelphia, USA: WB Saunders Company; 2000. p. 1911-2.
2. Narvencar KP, Rodrigues S, Nevrekar RP, Dias L, Dias A, Vaz M, Gomes E. Scrub typhus in patients reporting with acute febrile illness at a tertiary health care institution in Goa. *Indian J Med Res.* 2012 Dec;136:1020-24. [PubMed] [Google Scholar]
3. Mahajan SK. Scrub typhus. *J Assoc Physicians India.* 2005 Nov;53:954-8. [PubMed]
4. Kim K, Song J, Park E, Jin G. Scrub typhus: radiological and clinical findings in abdominopelvic involvement. *Jpn J Radiol.* 2017 Mar;35(3):101-8. [PubMed] [Google Scholar]
5. Aung-Thu, Supanaranond W, Phumiratanaprapin W, Phonrat B, Chinprasatsak S, Ratanajatroj N. Gastrointestinal manifestations of septic patients with scrub typhus in Maharat Nakhon Ratchasima Hospital. *Southeast Asian J Trop Med Public Health.* 2004 Dec;35(4):845-51. [PubMed] [Google Scholar]
6. ARDS Definition Task Force; Ranieri VM, Rubenfeld GD, Thompson BT, Ferguson ND, Caldwell E, Fan E, Camporota L, Slutsky AS. Acute respiratory distress syndrome: the Berlin Definition. *JAMA.* 2012 Jun;307(23):2526-33. [PubMed] [Google Scholar]
7. Keller CA, Hauptmann M, Kolbaum J, Gharaibeh M, Neumann M, Glatzel M, Fleischer B. Dissemination of *Orientia tsutsugamushi* and inflammatory response in a murine model of scrub typhus. *PLoS Negl Trop Dis.* 2014 Aug 14;8(8):e3064. [PubMed] [Google Scholar]
8. Chayakul P, Panich V, Silpapojakul K. Scrub typhus pneumonitis: an entity which is frequently missed. *Q J Med.* 1998 Aug;68:595-602. [PubMed] [Google Scholar]
9. Varghese GM, Trowbridge P, Janardhanan J, Thomas K, Peter JV, Mathews P, Abraham OC, Kavitha ML. Clinical

- profile and improving mortality trend of scrub typhus in South India. *Int J Inf Dis.* 2014 Jun;23:39-43. [PubMed] [Google Scholar]
10. Martyn C. The opposite of genomics. *QJM-Int J Med.* 2002;95(2):65-6. [PubMed] [Google Scholar]
 11. Wang CC, Liu SF, Liu JW, Chung YH, Su MC, Lin MC. Acute respiratory distress syndrome in scrub typhus. *Am J Trop Med Hyg.* 2007 Jun;76:1148-52. [PubMed] [Google Scholar]
 12. Rungta N. Scrub typhus: Emerging cause of multiorgan dysfunction. *Indian J Crit Care Med.* 2014 Aug;18:489-91. [PubMed] [Google Scholar]
 13. Prakash JA, Abraham OC, Mathai E. Evaluation of tests for serological diagnosis of scrub typhus. *Trop Doct.* 2006 Oct;36:212-3. [PubMed] [Google Scholar]
 14. Kim HH, Chung JH, Kim DM, Yun NR, Lee J, Kwon YE, Yoon SH, Lee SI, Han MA. The clinical characteristics of pleural effusion in scrub typhus. *BMC Infect Dis.* 2016 Jun;16:278. [PubMed] [Google Scholar]