



Research Article

Role of Chest Computed Tomography in Patients with COVID-19 for Triaging

Hajir Hassan Hussein¹, Abdulridha Taha Sarhan², Hawraa K Judi³

^{1,2}Department of Dentistry, Hilla University College, Babylon, Iraq.

³Department of Medical Physics, Hilla University College, Babylon, Iraq.

DOI: <https://doi.org/10.24321/0019.5138.202226>

I N F O

Corresponding Author:

Hajir Hassan Hussein, Department of Dentistry,
Hilla University College, Babylon, Iraq.

E-mail Id:

hajer.hassan@hilla-unc.edu.iq

Orcid Id:

<https://orcid.org/0000-0001-8140-4784>

How to cite this article:

Hussein HH, Sarhan AT, Judi HK. Role of Chest Computed Tomography in Patients with COVID-19 for Triaging. Special Issue - COVID-19 & Other Communicable Disease. 2022;165-170.

Date of Submission: 2021-10-28

Date of Acceptance: 10-02-2022

A B S T R A C T

Background: Coronavirus is detected utilising radiological images obtained by a simple scanning technique, such as computed tomography (CT). The current study looked at how chest CT changed during hospitalisation to better understand and diagnose COVID-19.

Aim: To see if a chest CT scan could help in COVID-19 patients with limited PCR diagnostic capabilities, early isolation, contact tracing, and therapy. Also to find the association of COVID-19 mortality with High aspartate aminotransferase (AST) and alanine aminotransferase (ALT) levels.

Method: The current study included 40 COVID-19 patients from Morgan Hospital Hilla. Two certified radiologists independently obtained and evaluated CT scans for 40 COVID-19 patients, and their findings were presented in Hillah city only referral hospital approved by the government to admit COVID-19 patients. Blood tests of COVID-19 people were examined for ALT (SGOT) and AST (SGPT) to evaluate how much damage they had to their livers.

Results: The percentages tree in bud, LAP, pleural elusion, crazy paving and honeycombing were present in lower percentage (4, 10%; 4, 10%; 6, 15%; 6, 15%; 2, 5% respectively), while, bilateral involvement and multiple lesions were found with higher percentage (32, 80%; 36, 90% respectively). Consolidations and GGO appeared with median percentage (12, 30%; 20, 50%) respectively. 12 patients were shown high level in SGOT (30%). 6 (15%) patients with SGPT were showed median percentage, and only 4 (10%) patients have increased alkaline phosphate.

Conclusion: We conclude that chest CT scan may aid in the identification and triage of suspected or confirmed COVID-19 patients in cities with limited PCR diagnostic capabilities.

Keywords: Computed Tomographic, Chest ST Scan, SGOT, SGPT, COVID-19



Introduction

Several cases of pneumonia with an unknown origin were reported in Wuhan, China's Hubei capital. Following that, the severe acute respiratory syndrome coronavirus-2 was discovered, which is a unique encased RNA coronavirus (SARS-CoV-2).¹ On January 30, 2020, the World Health Organization (WHO) announced a public health emergency of international significance, and on March 11, 2020, it proclaimed a global pandemic.² Some of the most common COVID 19 symptoms include fever, cough, and difficulty breathing. Isolating, testing, and finally treating patients with suspected or proven COVID-19 is the greatest technique for preventing widespread transmission, as it is with all epidemics.¹ To test the new COVID19, the Reverse Transcription Polymerase Chain Reaction (RT-PCR) method is the best option.^{3,4} However, the number of people who need to be tested is usually rather high, and this could be because coronavirus is highly transmissible, making healthcare systems overburdened. Several issues with testing efficiency, reliability, and results in availability have been found all of which have apparent consequences for disease control and transmission prevention.⁵ As a result, the majority of COVID-19 patients develop a significant lung infection, according to various clinical investigations.^{6,7} A chest CT scan, according to the findings, can be an excellent imaging technique for detecting lung-related disorders. For the detection of COVID-19 disease, CT scan pictures were employed in studies based on machine learning and deep learning technologies. Furthermore, despite its low sensitivity, chest radiography has long been considered the first-line imaging modality in the treatment of COVID-19 patients due to factors like availability and portability, which are especially important in resource-constrained settings.^{8,9} After a median of 25 days, 94 per cent of COVID-19 pneumonia patients exhibited persistent CT abnormalities, with ground glass opacities (GGO) being the most common, according to Wang Y et al.¹⁰ The crazy-paving pattern, on the other hand, was no longer visible 14 days after the onset of initial symptoms, indicating that the patient had recovered.¹¹ Typical chest radiograph and computed tomography (CT) scan findings in COVID-19 patients have recently been published in several reputable journals.^{9,12} In atypical or organising pneumonia, airspace opacities (similar to consolidation or ground-glass opacities) with a bilateral, peripheral, or bi-basal predominant distribution were regarded as typical symptoms. Pleural effusion is a rather uncommon complication. These specific CT findings are undeniably crucial in the diagnosis and/ or triaging of COVID-19.⁹ Coronaviruses are a type of virus that can cause disease in humans. Although the upper respiratory tract is the most common location of the infection, it can also damage the liver and intestine. More than one-third

to half of COVID-19 patients had liver involvement, as indicated by abnormal liver enzymes.⁸ The objective of this study was to find out if there was a link between COVID-19 patients' liver damage and their death rate, as well as to clarify a number of CT features and their ability to diagnose COVID-19 patients.

Method

The Ethics and Research Protocol Committee sought and obtained ethical clearance for this project before it began. In the current investigation, 40 data samples were taken from COVID-19 patients at Morgan Hospital Hilla, ranging in age from 25 to 70 years. Data were collected from hospitalised patients at Morgan Hospital Hilla, the only referral hospital approved by the government to admit COVID-19 patients in Hilla City, from May 4th to July 10th, 2021. The WHO interim advice was used to confirm COVID-19 instances.¹³ Epidemiological and clinical data, laboratory tests, radiological results, and progression and treatment information obtained from electronic medical records by nurses, physicians, and other professionals were used to analyse the data. The informed consent form has been signed by all the participants. It was difficult to include patients or the public in any level of this study's research. All the patients had a chest CT scan to see if they had viral pneumonia or not. All the patients were scanned in a supine position while holding their breath after taking a deep breath. The CT scan was obtained from the chest cavity's entrance to the diaphragm's bottom edge. Furthermore, all participants are tested for AST (SGOT) and ALT (SPOT) to determine the clinical significance of aberrant liver chemistries, their influence on COVID 19 patients, and their link with an increased mortality rate.

Inclusion Criteria

The information of admitted patients to the hospital from May 4th to July 10th, 2021 was obtained from the statistical department of the hospital. A questionnaire form was used for all patients with COVID 19 and liver damage, the following data were recorded: age, gender, date of infection, clinical symptoms appeared on the patients. Laboratory data where ever available were included in the study. Adults with RT-PCR-confirmed SARS-CoV-2 infection who underwent serologic testing for antibodies to SARS-CoV-2 (e.g. IgM, IgG, IgA, etc.) using an immunoassay.

Exclusion Criteria

The exclusion criteria were involved children less than 18 years of age; studies using serologic assays that have had Emergency Use Authorization revoked by the US Food and Drug Administration. As well as, the patients that were vaccinated by vaccine and all the patients were showed negative CT scan, negative PCR.

Results

The participants in this study were 40 COVID 19 patients who had their chest CT scans examined. The patients were 25 to 70 years old, with a mean age of 43 years, SD + 15, median 45, and mode 25. Figure 1 summarises the results of the correlation study, which show that tree in bud, LAP, pleural elusion, crazy paving, and honeycombing were all present in lower percentages (n = 4, 10%, n = 4, 10% n = 6, 15%, n = 6 patients, 15%, n = 2, 5%). Bilateral involvement and multiple lesions were seen in a lower percentage of cases in (n = 32 (80%), n = 36 (90%). Finally, the reference standard demonstrated consolidations in (n = 12 patients, 30% of 40) and GGO presence in the median proportion (n = 20, 50%). COVID-19 positivity was found in all of these patients.

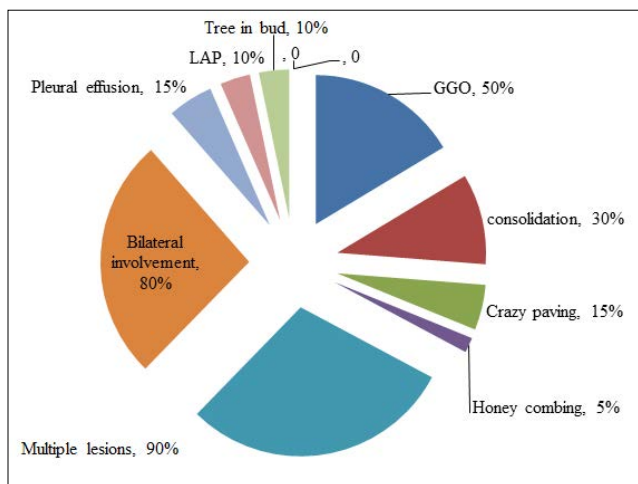


Figure 1. Pie Chart of CT Scan Features in Patients with COVID-19

As shown in Figure 2, 28 (70%) of the patients are male, representing a larger percentage, while 12 (30%) are female, representing a lower percentage. This result will be examined in a later section.

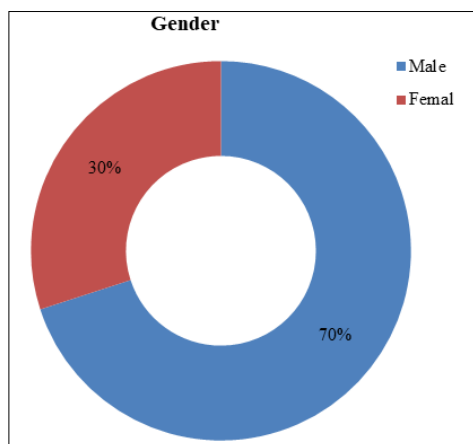


Figure 2. Pie Chart of Percentage of Gender in Patients with COVID-19

On the other hand, the early examination of 40 patients with COVID-19 yielded the following results: 12 patients had a high level of SGOT (30%), while 6 patients had increased SGPT levels by 15%. Only 4 patients have a high alkaline phosphate level of 10% (Figure 3).

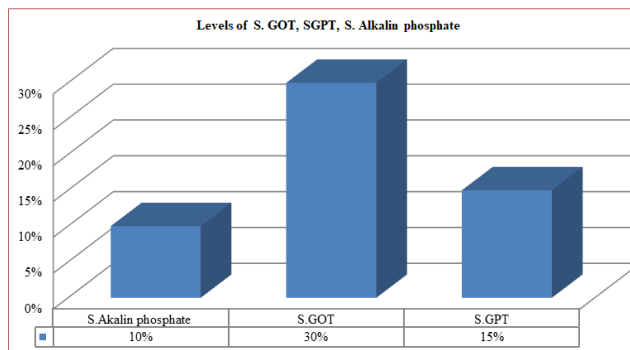


Figure 3. Correlation between SGOT, SGPT, S Alkaline Phosphate in Patients with COVID-19

Discussion

A chest CT scan is a highly sensitive imaging tool for detecting COVID-19 pneumonia.^{14,15} It is also thought to be more sensitive than chest radiography. The relative timing of chest radiography versus chest CT imaging in the treatment of the disease is one of the key reasons for this sensitivity. Because chest radiography is commonly performed at the onset of symptoms, when the disease may be minimal, the imaging results are typically trivial or inconspicuous. CT scans of the chest, on the other hand, are more likely to reveal COVID-19 typical imaging features because they are commonly performed when patients have a fairly severe illness at the start of the disease or later in its course.¹⁶ The CT scan findings in our patients were identical to those published, indicating that CT scans can play an essential role in the care of COVID-19 patients in Ghana, as they have elsewhere. Early detection and medical isolation are critical because there are currently no particular antiviral medications available to treat COVID-19. As a result, the gold standard for COVID-19 diagnosis is a laboratory-based reverse transcriptase-polymerase chain reaction (RT-PCR) test for respiratory specimens.^{17,18}

Because of many faults in the RT-PCR test, false-negative results might occur. The first is an incorrect swab test sampling location, while the second is a sample lacking virus particles or a procedural error. As a result, while the COVID-19 RT-PCR test has a high specificity, its sensitivity has been estimated to be between 59 and 71%.¹⁹ The key features of chest CT for coronavirus disease 2021 revealed in this study were crazy paving 15%, pleural elusion 15%, honeycombing 5%, LAP 10%, and ultimately tree in poor 10%. These findings are consistent with the findings of a chest CT scan of 28 patients with COVID 19 in Ghana, West Africa.²⁰⁻²²

Furthermore, from 40 patients with COVID 19, consolidations accounted for 30% of the total and GGO accounted for 50% of the total. These findings could be explained by the fact that GGO is thought to be the most important finding in early lung COVID-19, whereas most of the other criteria arise in later stages.¹¹ Furthermore, a CT scan of GGO at the peak of the disease shows a thicker interlobular septum, comparable to the “crazy paving” sign. Following that, several GGO lesions in the lungs emerged gradually, with thick consolidation in the lobes of the lungs in some patients. Some people with severe cases have diffuse lesions in both lungs, while others develop “white lung.” There are many signs of blood vessel penetration and an air bronchogram. GGOs and consolidation fade with no “crazy paving” appearance in the absorption or remission phase of sub-pleural parenchymal fibrosis lesions. As a result, CT can be used to track disease progression as well as assess the clinical severity and scope of COVID-19.^{22,23} Throughout the early stages of the disease, chest CT indicated small lobular and sub-segmental patchy GGOs, interstitial changes, and thickening vascular lumens, according to a recent study. A recent study found that 20/36 (56%) of early patients (2 days after onset of symptoms) had a normal CT scan.²⁴ According to current statistics, 28 (70%) of COVID-19 patients are male, compared to 12 (30%) females, and this pattern holds across all age categories. Females had a better chance of recovering than males, regardless of age, and experts believe that higher smoking rates are to blame, poorer hand-washing rates, preexisting respiratory illnesses, and biological variations between sexes are driving causes for higher infection and mortality among males. According to the findings of this study, men require more emergency treatment than women.²⁵ Another explanation for these findings is that hormonal response elements, such as putative androgen response elements (AREs) and estrogen response elements (OREs), trigger multiple innate immunity responses via a genetic mechanism, resulting in dimorphic innate immunity.²⁶ As a result, it appears that males are more susceptible to viral infection and produce fewer antibodies than females, according to various research. Women with a higher amount of TLR7 (Toll-like receptor 7 - protein sensor of RNA viruses) create more interferon, which boosts innate immunity.^{27,28} Women also have stronger inherent immunity and a better response to immunisations in diseases like cancer and HIV.²⁹ The most important therapeutically relevant finding was that 12 individuals had a 30% increase in SGOT, whereas 6 patients had a 15% increase in SGPT levels. Only four 4 patients have a high alkaline phosphate level of 10%. COVID-19 is connected to higher AST and ALT values, according to this study. These findings are consistent with previous studies, which found a strong relationship between elevated AST

and ALT levels and an increased risk of death in COVID-19 patients.³⁰ Ding J states that aspartate aminotransferase (AST) and alanine aminotransferase (ALT) were not shown to be linked with the risk of mortality in COVID-19 patients, in contrast to Wang Y et al. Finally, there are a few important limitations to keep in mind. To confirm the link between AST and ALT levels and the risk of mortality in COVID-19 patients in the future, large sample size is necessary. Future research should concentrate on the use of CT scans for detecting and staging cancer, as well as checking for recurrence and assessing treatment efficacy.

Conclusion

We conclude that chest CT scan may aid in the identification and triage of suspected or confirmed COVID-19 patients in cities with limited PCR diagnostic capabilities, as well as promote early isolation, contact tracing, and treatment, hence lowering community impact. Furthermore, high aspartate aminotransferase (AST) and alanine aminotransferase (ALT) levels should be considered the first indicators of COVID-19 patient mortality.

Acknowledgement

The author would like to thank the staff of Morgan Hospital in Hillah city.

Source of Funding: None

Conflict of Interest: None

References

1. Li J, Gong X, Wang Z, Chen R, Li T, Zeng D, Li M. Clinical features of familial clustering in patients infected with 2019 novel coronavirus in Wuhan, China. *Virus Res.* 2020 Sep;286:198043. [PubMed] [Google Scholar]
2. World Health Organization. Covid-19 situation report. WHO. 2020;31(2):61-6.
3. de Waal MJ. A comparative overview. Chapter - Exploring the Law of Succession: Studies National, Historical and Comparative. 2012;2002:1-26. [Google Scholar]
4. Uhteg K, Jarrett J, Richards M, Howard C, Morehead E, Geahr M, Gluck L, Hanlon A, Ellis B, Kaur H, Simner P, Carroll KC, Mostafa HH. Comparing the analytical performance of three SARS-CoV-2 molecular diagnostic assays. *J Clin Virol.* 2020 Jun;127(20):104384. [PubMed] [Google Scholar]
5. Lippi G, Simundic AM, Plebani M. Potential preanalytical and analytical vulnerabilities in the laboratory diagnosis of coronavirus disease 2019 (COVID-19). *Clin Chem Lab Med.* 2020 Jun;58(7):1070-6. [PubMed] [Google Scholar]
6. Lieveld AWE, Kok B, Schuit FH, Azijli K, Heijmans J, van Laarhoven A, Assman NL, Kootte RS, Olgers TJ,

- Nanayakkara PWB, Bosch FH. Diagnosing COVID-19 pneumonia in a pandemic setting: Lung Ultrasound versus CT (LUVCT) – a multicentre, prospective, observational study. *ERJ Open Res.* 2020 Dec;6(4):00539-2020. [PubMed] [Google Scholar]
7. Turkoglu M. COVID-19 detection system using chest CT images and multiple kernels-extreme learning machine based on deep neural network. *Ing Rech Biomed.* 2021 Aug;42(4):207-14. [PubMed] [Google Scholar]
 8. World Health Organization [Internet]. Clinical management of severe acute respiratory infection when novel coronavirus (nCoV) infection is suspected: interim guidance, 25 January 2020. Available from: <https://apps.who.int/iris/handle/10665/330854> [Google Scholar]
 9. Wong HY, Lam HY, Fong AH, Leung ST, Chin TW, Lo CS, Lui MM, Lee JC, Chiu KW, Chung TW, Lee EY, Wan EY, Hung IF, Lam TP, Kuo MD, Ng MY. Frequency and distribution of chest radiographic findings in patients positive for COVID-19. *Radiology.* 2020 Aug;296(2):E72-8. [PubMed] [Google Scholar]
 10. Wang Y, Dong C, Hu Y, Li C, Ren Q, Zhang X, Shi H, Zhou M. Temporal changes of CT findings in 90 patients with COVID-19 pneumonia: a longitudinal study. *Radiology.* 2020 Aug;296(2):E55-64. [PubMed] [Google Scholar]
 11. Pan F, Ye T, Sun P, Gui S, Liang B, Li L, Zheng D, Wang J, Hesketh RL, Yang L, Zheng C. Time course of lung changes on chest CT during recovery from 2019 Novel Coronavirus (COVID-19) pneumonia. *Radiology.* 2020 Jun;295(3):715-21. [PubMed] [Google Scholar]
 12. Chung M, Bernheim A, Mei X, Zhang N, Huang M, Zeng X, Cui J, Xu W, Yang Y, Fayad ZA, Jacobi A, Li K, Li S, Shan H. CT imaging features of 2019 novel coronavirus (2019-nCoV). *Radiology.* 2020 Apr;295(1):202-7. [PubMed] [Google Scholar]
 13. World Health Organization. WHO Director-General's opening remarks at the media briefing on COVID-19. 11 March 2020. World Health Organization; 2020.
 14. Wang H, Wei R, Rao G, Zhu J, Song B. Characteristic CT findings distinguishing 2019 novel coronavirus disease (COVID-19) from influenza pneumonia. *Eur Radiol.* 2020 Sep;30(9):4910-7. [PubMed] [Google Scholar]
 15. Di Gennaro F, Pizzol D, Marotta C, Antunes M, Racialbuto V, Veronese N, Smith L. Coronavirus diseases (COVID-19) current status and future perspectives: a narrative review. *Int J Environ Res Public Health.* 2020 Apr;17(8):2690. [PubMed] [Google Scholar]
 16. Zhou Z, Guo D, Li C, Fang Z, Chen L, Yang R, Li X, Zeng W. Coronavirus disease 2019: initial chest CT findings. *Eur Radiol.* 2020 Aug;30(8):4398-406. [PubMed] [Google Scholar]
 17. Huang C, Wang Y, Li X, Ren L, Zhao J, Hu Y, Zhang L, Fan G, Xu J, Gu X, Cheng Z, Yu T, Xia J, Wei Y, Wu W, Xie X, Yin W, Li H, Liu M, Xiao Y, Gao H, Guo L, Xie J, Wang G, Jiang R, Gao Z, Jin Q, Wang J, Cao B. Clinical features of patients infected with 2019 novel coronavirus in Wuhan, China. *Lancet.* 2020 Feb;395(10223):497-506. [PubMed] [Google Scholar]
 18. Corman VM, Landt O, Kaiser M, Molenkamp R, Meijer A, Chu DK, Bleicker T, Brünink S, Schneider J, Schmidt ML, Mulders DG, Haagmans BL, van der Veer B, van den Brink S, Wijsman L, Goderski G, Romette JL, Ellis J, Zambon M, Peiris M, Goossens H, Reusken C, Koopmans MP, Drosten C. Detection of 2019 novel coronavirus (2019-nCoV) by real-time RT-PCR. *Euro Surveill.* 2020 Jan;25(3):2000045. [PubMed] [Google Scholar]
 19. Fang Y, Pang P. Sensitivity of Chest CT for COVID-19: Comparison to RT-PCR. *Radiology.* 2020 Aug;296:15-7. [PubMed] [Google Scholar]
 20. Sarkodie BD, Mensah YB, Ayetey H, Dzefi-Tettey K, Brakohiapa E, Kaminta A, Idun E. Chest Computed Tomography findings in patients with corona virus disease 2019 (COVID-19): An initial experience in three centres in Ghana, West Africa. *J Med Imaging Radiat Sci.* 2020 Dec;51(4):604-9. [PubMed] [Google Scholar]
 21. Xue H, Jin Z. The appropriate position of radiology in COVID-19 diagnosis and treatment -current status and opinion from China. *Chinese J Acad Radiol.* 2020;3(1):1-3. [PubMed] [Google Scholar]
 22. Wu J, Wu X, Zeng W, Guo D, Fang Z, Chen L, Huang H, Li C. Chest CT findings in patients with coronavirus disease 2019 and its relationship with clinical features. *Invest Radiol.* 2020 May;55(5):257-61. [PubMed] [Google Scholar]
 23. Zhao W, Zhong Z, Xie X, Yu Q, Liu J. Relation between chest CT findings and clinical conditions of coronavirus disease (covid-19) pneumonia: A multicenter study. *Am J Roentgenol.* 2020 May;214(5):1072-7. [PubMed] [Google Scholar]
 24. Bernheim A, Mei X, Huang M, Yang Y, Fayad ZA, Zhang N, Diao K, Lin B, Zhu X, Li K, Li S, Shan H, Jacobi A, Chung M. Chest CT findings in coronavirus disease-19 (COVID-19): relationship to duration of infection. *Radiology.* 2020 Jun;295(3):200463. [PubMed] [Google Scholar]
 25. Betron M, Gottert A, Pulerwitz J, Shattuck D, Stevanovic-Fenn N. Men and COVID-19: adding a gender lens. *Glob Public Health.* 2020 Jul;15(7):1090-2. [PubMed] [Google Scholar]
 26. Hannah MF, Bajic VB, Klein SL. Sex differences in the recognition of and innate antiviral responses to Seoul virus in Norway rats. *Brain Behav Immun.* 2008 May;22(4):503-16. [PubMed] [Google Scholar]
 27. Berghöfer B, Frommer T, Haley G, Fink L, Bein G, Hackstein H. TLR7 Ligands Induce Higher IFN- α Production

- in Females. *J Immunol.* 2006 Aug;177(4):2088-96. [PubMed] [Google Scholar]
28. Pisitkun P, Deane JA, Difilippantonio MJ, Tarasenko T, Satterthwaite AB, Bolland S. Autoreactive B cell responses to RNA-related antigens due to TLR7 gene duplication. *Science.* 2006 Jun;312(5780):1669-72. [PubMed] [Google Scholar]
29. Klein SL, Flanagan KL. Sex differences in immune responses. *Nat Rev Immunol.* 2016 Oct;16(10):626-38. [PubMed] [Google Scholar]
30. Wang Y, Shi L, Wang Y, Yang H. An updated meta-analysis of AST and ALT levels and the mortality of COVID-19 patients. *Am J Emerg Med.* 2021 Feb;40:208-9. [PubMed] [Google Scholar]