



Case Report

# A Rare Case of Gastrointestinal Canthariasis Caused by *Alphitobius Diaperinus*

Rina Tilak<sup>1</sup>, Anmol Sharma<sup>2</sup>, Suraj Kapoor<sup>1</sup>, Swati Bajaj<sup>1</sup>

<sup>1</sup>Department of Community Medicine, Armed Forces Medical College, Pune, Maharashtra, India.

<sup>2</sup>Base Hospital, Delhi Cantt, Delhi, India.

DOI: <https://doi.org/10.24321/0019.5138.202311>

## I N F O

### Corresponding Author:

Rina Tilak, Department of Community Medicine, Armed Forces Medical College, Pune, Maharashtra, India.

### E-mail Id:

[rinatilak@hotmail.com](mailto:rinatilak@hotmail.com)

### Orcid Id:

<https://orcid.org/0000-0003-3781-0210>

### How to cite this article:

Tilak R, Sharma A, Kapoor S, Bajaj, S. A Rare Case of Gastrointestinal Canthariasis Caused by *Alphitobius Diaperinus*. J Commun Dis. 2023;55(1):74-77.

Date of Submission: 2023-03-07

Date of Acceptance: 2023-04-22

## A B S T R A C T

Canthariasis is a human/ animal infestation by larval stages of coleopteran insects - the beetles. This study reports a rare case of gastrointestinal canthariasis caused by *Alphitobius diaperinus*.

A six-year-old boy presented with complaints of pain abdomen associated with non-bilious, non-blood-stained vomiting for 15 days and a history of passage of worm-like creatures via stools and occasionally in the vomitus. All investigations were normal barring the presence of small worm-like creatures (insect larvae) in stools on naked-eye examination. Treatment with anthelmintics did not provide any relief with continued infestation over the past 3 months. The worms in the stool were identified as larvae of lesser mealworm - *Alphitobius diaperinus*. Dietary history of consumption of dry fruits infested with *Alphitobius diaperinus* determined the source of the infestation and the diagnosis, and the appropriate management was thus initiated.

This report implicates *Alphitobius diaperinus* as a cause of gastrointestinal canthariasis and highlights the importance of dietary history to effectively manage gastrointestinal canthariasis.

**Keywords:** *Alphitobius diaperinus*, Canthariasis, Gastrointestinal, Lesser Mealworm, Stool

## Introduction

Canthariasis is a condition that affects humans and animals and causes infestation of the gastrointestinal tract, urogenital system, and subcutaneous and nasal sinuses by the developing larvae of Coleopteran insects - beetles.<sup>1-4</sup> Gastrointestinal canthariasis is a common infestation in the paediatric age group often leading parents to seek medical attention.<sup>5-10</sup> The clinical presentation of canthariasis is usually broad and often unspecific posing a diagnostic challenge to the treating physician leading to empirical treatment with anthelmintics. Stored food materials, dry fruits, breakfast cereals, or precooked cereals

have long been considered to serve as a microhabitat for both adult and larval stages of beetles, thus providing a suitable environment for the agent (beetle) and host (human) interaction. Cases of canthariasis caused by various species of beetles have been reported worldwide, however, canthariasis caused by *Alphitobius diaperinus* has not been documented so far.

*Alphitobius diaperinus* (Panzer) (Coleoptera: Tenebrionid), commonly called the lesser mealworm, is usually found infesting grain products, especially in poorly maintained processing plants.<sup>11</sup> It has been associated with food grains viz. wheat, rice, barley, soybeans, cowpeas,



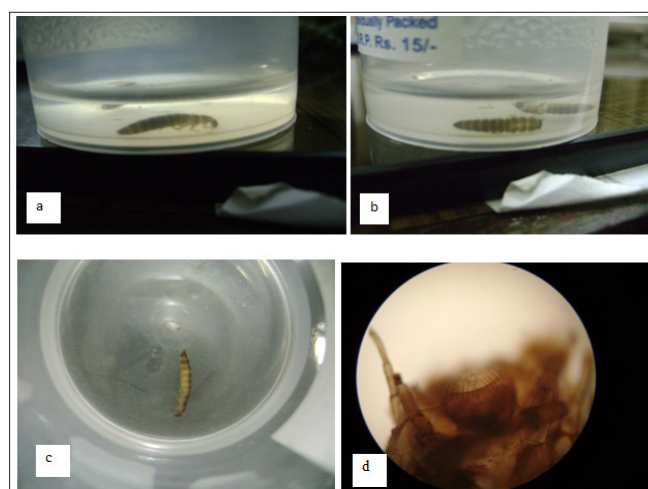
peanuts, breakfast cereals, precooked cereals, and dry fruits. The lesser mealworm is ideally suited to warm and humid conditions and hence is abundantly found infesting various food materials including stored grains/ready-to-eat cereals, and stored dry fruits. It is known to be a commercial menace in poultry as well.<sup>12</sup> It has also been documented to transmit various infections caused by *Salmonella*, *Campylobacter*, *Escherichia*, fungi, parasites, and viruses.<sup>13,14</sup> The lesser mealworm, *Alphitobius diaperinus*, has nonetheless never been documented as the causative organism for canthariasis. This report describes the first case of gastrointestinal canthariasis caused by *Alphitobius diaperinus* larvae in a six-year-old boy from an urban city in western India.

### Case Report

The case was a six-year-old boy, brought by his parents to the clinic of a tertiary care hospital with complaints of pain abdomen associated with non-bilious, non-blood-stained vomiting for 15 days. The parents also reported a history of the passage of worms (about 7-12) in stools that appeared cylindrical and dark to the naked eye and were found to float on water when the stool was examined by the parents. Occasional sightings of worms in vomitus were also documented. There was no history of fever, loose stools, haematemesis, or melena. The mother had an uneventful antenatal history with the index case (child) having an uneventful postnatal period and all developmental milestones were achieved as per age. The boy had been vaccinated as per the existing national immunisation schedule of India. There was no history of similar presentation among the family members barring an occasional episode in the older brother aged 11 years. The child lived with his parents in a cemented house in an urban area. There was no history of contact with animals or

exposure to mud. On physical examination, the child was active and playful. His height and weight were within normal growth parameters. On clinical examination, his vitals were found to be stable. General examination showed no pallor, icterus, cyanosis, clubbing, lymphadenopathy, or pedal oedema. Systemic examination including per abdomen and rectal examination was normal. Routine biochemistry and haematological investigations were within normal limits. A routine examination of the stool showed the presence of worm-like creatures. Besides this, no other findings were observed on routine and microscopic examinations of stool.

The child was started on anthelmintic medication and supportive care however, there was no improvement in his clinical condition. The advice of the entomologist was sought post three months of treatment with anthelmintics for identification of the worm-like creatures present in the stool of the child. On examination of the samples, it was confirmed to be the larval stage of the lesser mealworm - *Alphitobius diaperinus*. The dorsal, lateral, and ventral views and the mouthparts of *Alphitobius diaperinus* received as samples have been presented in Figure 1. As the lesser mealworm is known to infest stored grains, breakfast cereals, dry fruits, etc. a detailed dietary history was taken. It was noted that the child although consuming normal home-cooked food, was excessively fond of snacking on stored dry fruits. The source of infestation was thus traced to the stored dry fruits (dried prunes, almonds, and cashews which were found infested) which the child was snacking exclusively. The parents were advised that the consumption of stored and infested dry fruits should be stopped forthwith and the child should be monitored for similar episodes. On review after 15 days, the child was found to have made an uneventful recovery. There was no fresh evidence of the passage of worms in the stool or vomitus when followed for a further period of one month.



**Figure 1. Larvae of *Alphitobius Diaperinus* Collected from Stool Sample (a) Top View (b) Dorsal View (c) Lateral View (d) Mouthparts**

**Table 1. Documented Cases of Canthariasis Caused by Various Coleopteran Beetles**

S. No.	Place of Occurrence	Age of Patient	Year	Coleoptera Species Incriminated	Authors, Reference
1.	USA	8 months	1946	<i>Tenebrio molitor</i>	Palmer <sup>5</sup>
2.	Iran	10 years	2018	<i>Tenebrio molitor</i>	Aelami et al. <sup>6</sup>
3.	China	8 months	2016	<i>Lasioderma serricorne</i>	Sun et al. <sup>7</sup>
4.	Venezuela	9 years	2019	<i>Tenebrio</i>	Cazorla-Perfetti et al. <sup>8</sup>
5.	Malaysia	1 year	2015	<i>Lasioderma serricorne</i>	Mokhtar et al. <sup>9</sup>
6.	India	3 years	2016	Not found	Varghese et al. <sup>10</sup>
7.	UK	9 years	1946	<i>Tenebrio molitor</i>	Bateman <sup>15</sup>
8.	Columbia	32 years (HIV-positive)	2018	<i>Tenebrio molitor</i>	Rodriguez-Morales et al. <sup>16</sup>
9.	Jordan	29 years (SLE + AHA)*	2014	<i>Stegobium panicullum</i>	Smadi et al. <sup>17</sup>
10.	India	Eighteen children (2-5 years)	1999-2008	Not found	Karthikeyan et al. <sup>18</sup>

\*SLE: Systemic Lupus Erythematosis; AHA: Autoimmune Haemolytic Anaemia

## Discussion

Canthariasis is a rare disease caused due to infestation by beetle larvae. Cases of human infestations have also been reported and multiple species of beetles have been incriminated. Species of beetles reported having caused canthariasis have been listed in Table 1. Canthariasis predominantly affects children belonging to rural or suburban areas; the infestation is primarily localised to the gastrointestinal system and rarely to the urogenital system. Risk factors for infestation include consumption of infested food items or direct contact with soil, dung, or poultry which are often linked to poor hygiene. Our case, a child residing in an urban location, was living in hygienic conditions with no exposure to cattle and poultry. Though many species of beetles have been documented to infest humans, this is the first case report of gastrointestinal canthariasis due to *Alphitobius diaperinus*. The adults are broadly-oval, convex, brownish-black, and shiny with an approximate length of 5.8 to 6.3 mm. Antennae are densely packed with small yellowish hair with a lighter terminal segment. The head is deeply emarginated in the anterior with a distinctive clypeal groove and coarsely punctured surface. The eyes are also emarginated. The larvae of *Alphitobius* outwardly resemble true mealworms (*Tenebrio spp.*) in having three pairs of legs and a segmented body that tapers posteriorly. They measure approximately 7 to 11 mm in length when fully grown. Freshly emerged larvae are pale in colouration but turn dark yellowish-brown by the time they turn into the third instar. There are approximately 6 to 11 larval instars.<sup>11</sup>

Canthariasis was documented as early as 1811 by Bateman and thereafter it was only in 1920 that a case of canthariasis was reported from India with a report of a similar case in 1946 from the USA.<sup>1,4,15</sup> However, the number of publications on the subject remains abysmally low. Canthariasis cases have also been reported amongst immune-compromised patients, especially in those suffering from lupus.<sup>16,17</sup>

Clinically, patients of gastrointestinal canthariasis generally present with a history of loss of appetite, diarrhoea, cramps in the abdomen, and continued fever. Gradual emaciation is another significant evidence of gastrointestinal canthariasis.<sup>4</sup> Our case, however, did not present with typical symptoms and had only vomiting and intermittent loose stools. While most physicians treat such cases with anthelmintic and supportive management, our case showed minimal improvement with medication. Being a rare occurrence, it becomes important to elicit detailed dietary and environmental history with the involvement of the caretakers especially in the case of paediatric patients to ascertain and eliminate the cause of infestation. The case highlights the need to determine the causative factor and eliminate the same for alleviating the symptoms and permanent relief. There has been one case of documented fatality<sup>16</sup>; however, a long-standing neglected case may develop other serious complications as well. Most cases have been solitary; nonetheless, cases with multiple infestations have been reported in northeast India with eighteen cases of canthariasis documented from the same neighbourhood.<sup>18</sup> Thus it is important to emphasise that primary prevention, in the form of maintenance of

environmental, personal, and dietary hygiene, is essential for the prevention of canthariasis. Saline purgative and oral metronidazole although help in removing the insects from the human digestive tract,<sup>18</sup> yet they do not address the problem permanently, especially when there is a continued source of infestation like consumption of infested food materials. Removal/ avoidance of consumption of infested food materials is the only solution that is long-term and effective in the management of gastrointestinal canthariasis. Additionally, stringent quality control of stored food grains and breakfast cereals/ precooked cereals and dry fruits would ensure a reduction in cases of canthariasis.

## Conclusion

Gastrointestinal canthariasis may be caused due to many coleopteran insects. This study reports a rare case of gastrointestinal canthariasis due to larvae of *Alphitobius diaperinus*, which infests ready-to-eat stored food products. It is thus recommended that dietary history should be necessarily undertaken for the effective management of gastrointestinal canthariasis, especially due to *Alphitobius diaperinus*, in addition to the routine administration of anthelmintics.

**Source of Funding:** None

**Conflict of Interest:** None

## References

1. Gałęcki R, Michalski MM, Wierzchosławski K, Bakula T. Gastric canthariasis caused by invasion of mealworm beetle larvae in weaned pigs in large-scale farming. BMC Vet Res. 2020;16:439. [PubMed] [Google Scholar]
2. Lewis DJ. *Coleoptera* of medical interest in the Sudan Republic. Proceedings of the Royal Entomological Society of London Series A, General Entomology. Wiley Online Library. 1958;33:37-42. [Google Scholar]
3. Théodoridès J. The parasitological, medical, and veterinary importance of Coleoptera. Acta Trop. 1950;7:47-60. [Google Scholar]
4. Park SJ, Ha NR, Ryu SY, Chae JS, Kim HC, Park J, Choi KS, Yu DH, Park BK. Subcutaneous canthariasis due to *Tenebrio molitor* larva (*Coleoptera*: Tenebrionidae) in *Egretta intermedia*. J Dairy Vet Anim Res. 2016;3(4):134-7.
5. Palmer ED. Intestinal canthariasis due to *Tenebrio molitor*. J Parasitol. 1946;32:54-5. [PubMed] [Google Scholar]
6. Aelami MH, Khoei A, Ghorbani H, Seilanian-Toosi F, Poustchi E, Hosseini-Farash BR, Moghaddas E. Urinary canthariasis due to *Tenebrio molitor* larva in a ten-year-old boy. J Arthropod Borne Dis. 2019;13(4):416-9. [PubMed] [Google Scholar]
7. Sun X, Wang LF, Feng Y, Xie H, Zheng XY, He A, Karim MR, Lv ZY, Wu ZD. A case report: a rare case of infant gastrointestinal canthariasis caused by larvae of *Lasioderma serricorne* (Fabricius, 1792) (*Coleoptera*: Anobiidae). Infect Dis Poverty. 2016;5:34. [PubMed] [Google Scholar]
8. Cazorla-Perfetti D, Acosta-Quinter M, Morales-Moreno P. First report of a case of canthariasis caused by a darkling beetle larva (*Coleoptera*: Tenebrionidae) in Venezuela. Rev Nicaragüense Entomol. 2019;183:3-13. [Google Scholar]
9. Mokhtar AS, Sridhar GS, Mahmud R, Jeffery J, Lau YL, Wilson JJ, Abdul-Aziz NM. First case report of canthariasis in an infant caused by the larvae of *Lasioderma serricorne* (*Coleoptera*: Anobiidae). J Med Entomol. 2016;53(5):1234-7. [PubMed] [Google Scholar]
10. Varghese SM, Austoria AJ, Koshy M, Abraham JM. A rare and interesting case of scarabiasis. Int J Contemp Pediatr. 2019;6:2709-11. [Google Scholar]
11. Spilman TJ. Darkling beetles (Tenebrionidae, *Coleoptera*). In: Gorham JR, editor. Insect and mite pests in food. United States of America: United States Department of Agriculture, Agricultural Handbook; 1991;185-214. [Google Scholar]
12. Rumbos CI, Karapanagiotidis IT, Mente E, Athanassiou CG. The lesser mealworm *Alphitobius diaperinus*: a noxious pest or a promising nutrient source? Rev Aquacult. 2019;11(4):1418-37. [Google Scholar]
13. Roche AJ, Cox NA, Richardson LJ, Buhr RJ, Cason JA, Fairchild BD, Hinkle NC. Transmission of Salmonella to broilers by contaminated larval and adult lesser mealworms, *Alphitobius diaperinus* (*Coleoptera*: Tenebrionidae). Poult Sci. 2009;88(1):44-8. [PubMed] [Google Scholar]
14. De las Casas E, Pomeroy BS, Harein PK. Infection and quantitative recovery of *Salmonella typhimurium* and *Escherichia coli* from within the lesser mealworm, *Alphitobius diaperinus* (Panzer). Poult Sci. 1968;47:1871-5. [PubMed] [Google Scholar]
15. Bateman T. An account of the larvae of two species of insects discharged from the human body. Edinb Med Surg J. 1811;7(25):41-8. [PubMed] [Google Scholar]
16. Rodriguez-Morales AJ, Vera-Ospina JJ, Berthel-Vergara JM, Silvera-Arenas LA, Villamil-Gómez WE. Accidental ulcer infestation due *Tenebrio molitor* in an AIDS patient: canthariasis. Int J Infect Dis. 2018;73:253-4. [Google Scholar]
17. Smadi R, Amr ZS, Katbeh-Bader A, Obidat N, Tawarah M, Hasan H. Facial myiasis and canthariasis associated with systemic lupus panniculitis: a case report. Int J Dermatol. 2014;53:1365-9. [PubMed] [Google Scholar]
18. Karthikeyan G, Ganesh R, Sathiasakeran M. Scarabiasis. Indian Pediatr. 2008;45(8):697-9. [PubMed] [Google Scholar]