

Research Article

# Cryptogenic Organizing Pneumonia: A Series of 25 Cases

Vikas Ratnaparkhe<sup>1</sup>, Kavita Upadhyay<sup>2</sup>

<sup>1</sup>Consultant Physician, Dr. Hedgewar Hospital, Aurangabad, Maharashtra, India.

<sup>2</sup>Resident DNB (General Medicine), Dr. Hedgewar Hosiptal, Aurangabad, Maharashtra, India.

DOI: <https://doi.org/10.24321/2455.7048.201921>

## I N F O

### Corresponding Author:

Vikas Ratnaparkhe, Consultant Physician, Dr. Hedgewar Hospital, Aurangabad.

### E-mail Id:

[vikasrr25@gmail.com](mailto:vikasrr25@gmail.com)

### Orcid Id:

<https://orcid.org/0000-0002-7731-2921>

### How to cite this article:

Ratnaparkhe V, Upadhyay K. Cryptogenic Organizing Pneumonia: A series of 25 Cases. *Epidem Int* 2019; 4(4): 25-31.

Date of Submission: 2020-01-20

Date of Acceptance: 2020-02-05

## A B S T R A C T

**Introduction:** Cryptogenic Organizing Pneumonia (COP) earlier known as 'Bronchiolitis Obliterans with Organizing Pneumonia' (BOOP), is a rare lung condition in which the bronchioles, alveoli and the walls of small bronchi become inflamed and plugged with connective tissue. The condition is called "cryptogenic" because the cause is unknown.

**Aim:** To study clinical and radiological spectrum of cases reported as COP.

**Materials and Methods:** This is an observational study including secondary data analysis. The medical records, clinical and radiological profiles of COP patients, visiting Dr. Hedgewar Hospital, Aurangabad (2016-2019) were analyzed.

**Result:** The Study included 25 cases. The urban: rural ratio was 14:11. Male: Female ratio was 14:11. The presenting symptoms were mainly Progressive dyspnoea (72%) and Dry cough (68%). Co-morbidities were observed in 72% patients and 28% patients required assisted ventilation. The radiological features were bilateral patchy opacities in 36%, unilateral consolidation in 24%, reticulo-nodular opacities in 8% patients. 32% of Chest Xray were reported as normal. HRCT Lung showed Ground Glass Opacities in 44%, Sub pleural And Interstitial Thickening in 23%, Multiple Nodular Enhancements in 14%, Cystic Changes and Traction Bronchiectasis in 15% and Others (Crazy paving, cavitary changes) in 4% patients. Steroids were administered in 48% patients. The mortality was 20%. The survivors (80% patients) showed clinical improvement. Elderly population, co-morbidities, smoking and ventilator support were the high risk factors for the outcome.

**Conclusion:** COP has varied clinico- radiological spectrum. A high index of suspicion will lead to proper diagnosis and management resulting in better outcome. The steroid therapy resulted in better outcome.

**Keywords:** Cryptogenic Organizing Pneumonia (COP), Radiology, Ventilator Support, Comorbidities, Steroids

## Introduction

Cryptogenic Organizing Pneumonia (COP) is a rare lung condition. The small airways are inflamed and clogged with connective tissue. Alveoli, bronchioles, and the walls of small bronchi are mainly affected. As the cause is unknown, the condition is called "cryptogenic".<sup>1</sup>

It is now considered as a rare variety of interstitial lung diseases (ILDs).<sup>2</sup> There are only a few case reports on COP from India.

The first Indian Study on 'Cryptogenic Organizing Pneumonia' was done by T Sen and Z F Udawadia, published in APRIL 2008.<sup>3</sup> This study included biopsy proven cases of COP and their clinical and radiological profile from a single centre. Another study was published in 2018 in Turkish Thoracic journal by Baha A et al.<sup>4</sup> concluded that the clinic-radiological findings and prognosis were similar in patients of Cryptogenic and Secondary Organizing Pneumonia. There are only few case reports of COP from India. Our study is based on the clinical and Radiological profile of patients reported as COP from our institution. Response to treatment and prognosis of patients has been studied.

## Materials and Methods

This is a retrospective, observational and descriptive study. The medical records of all the patients reported as COP visiting Dr. Hedgewar Hospital, Aurangabad (2016-2019) were analyzed. The hospital is one of the main referral centers of central Maharashtra.

We studied the clinical and radiological profiles of these patients and responsiveness to the treatment. For all the patients we recorded the clinical history and routine laboratory tests including Erythrocyte Sedimentation Rate (ESR), chest X-rays and Computed Tomography (CT) scan of the chest. The results of twenty five patients reported as COP were included in the present study.

As given in Literature the common chest X- Ray findings of COP include consolidation, unilateral or bilateral patchy areas usually peripheral, subpleural and peribronchovascular regions.<sup>5</sup>

The common radiological features of COP in HRCT Lung consist of<sup>6</sup> Patchy areas of consolidation with a predominantly subpleural and/or peribronchial distribution, small, ill-defined peribronchial or peribronchiolar nodules, large nodules or masses, bronchial wall thickening or dilatation in the abnormal lung region, a perilobular pattern with ill-defined linear opacities, ground glass opacities or crazy paving. The reverse halo sign (atoll sign) is considered to be highly specific, although only seen in -20% of patients with COP.<sup>5,6</sup>

The Histopathological hallmark of organizing pneumonia is the presence of masson bodies (buds of granulation

tissue) consisting of fibroblasts-myofibroblast embedded in connective tissue. It extends from one alveolus to other via interalveolar pores of Kohn. This gives characteristic "butterfly" appearance. Buds may extend into the bronchioles and obstruct the lumen (bronchiolitis obliterans of the proliferative type). Mild interstitial inflammation is present in areas of organizing pneumonia.<sup>1,7</sup>

## Clinical Analysis

The mean age of presentation in our study was 58 years (ranging from 30 years to 81 years). Fourteen out of total twenty five patients were males and eleven were females. One of the Indian studies published in 2008<sup>3</sup> showed female dominance and male: female ratio noted in that study was 1:3. The cause of this is unknown.

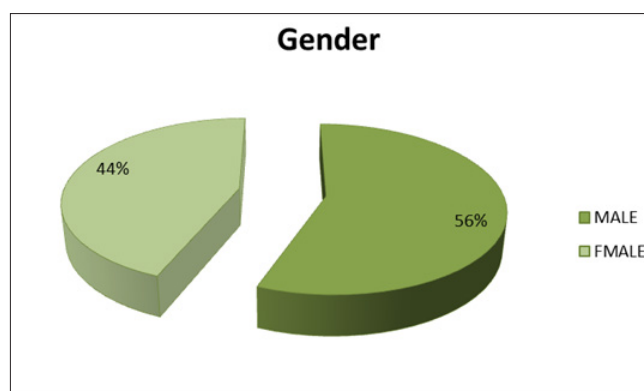


Figure 1. Showing gender distribution of study population

Out of twenty five patients studied fourteen were from urban area, six of them were males and eight were females. Eleven patients were from rural area. Eight of them were males. It was observed that there was male dominance in rural area and female dominance in urban area. The reason for such distribution needs further studies.

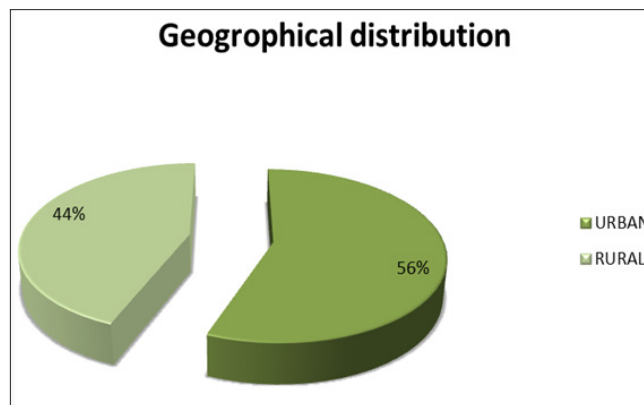
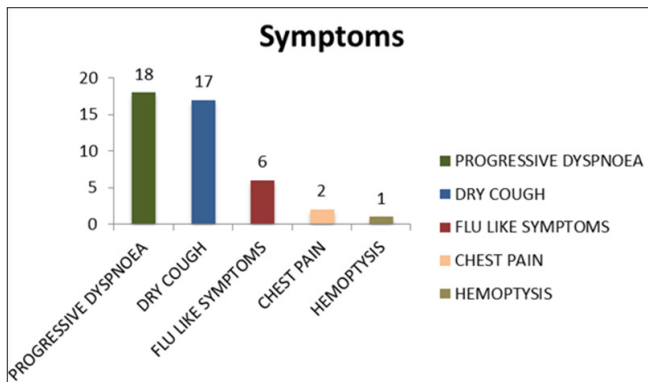


Figure 2. Showing geographical distribution of population

The presenting symptoms of our study were classified under five categories as:

- Dry cough - 68%
- Progressive dyspnoea - 72%
- Flu like symptoms - 24%
- Chest pain - 8%
- Hemoptysis - 4%



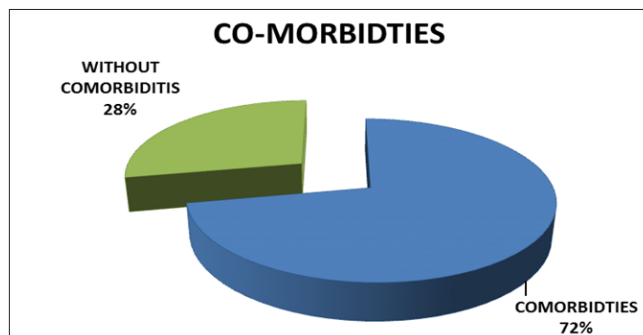
**Figure 3. Distribution of symptoms and patients: progressive dyspnea: 18, Dry cough: 17, flu like symptoms: 6, chest pain: 2, hemoptysis: 1**

An Indian study reported<sup>3</sup> Dry cough as the commonest presenting symptom being present in 76% of the patients, followed by breathlessness in 65% of patients and sputum production in 35%. Fever and constitutional symptoms were present in 24% and 15% of patients respectively. More rarely encountered symptoms included hemoptysis, wheeze, and chest pain. Similar findings were noted in a study done by Baha A et al.<sup>4</sup>

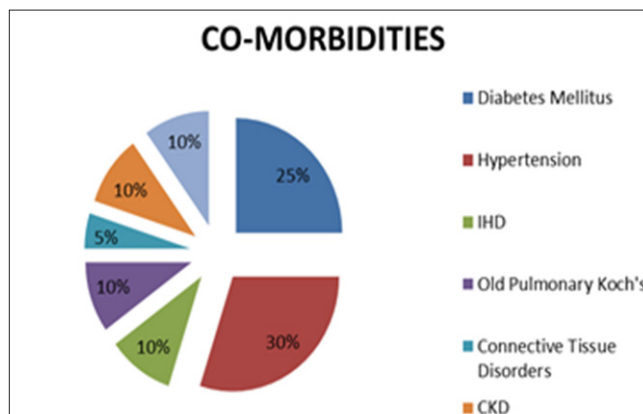
Out of 25 patients studied, 20% (5 patients) were chronic bidi smokers. 80% (20 patients) were nonsmokers (we doubt about the Ex-smoking habits of male patients).<sup>4</sup> 4 out of 5 smokers were from rural area. The study done by Sen and Udwadia has shown different results in this regard. In their study 14% were smokers, 32% were ex-smokers and 54% were nonsmokers.<sup>3</sup> An Italian study by Cazzato S et al demonstrated 54% smokers and 32% as non-smokers<sup>(8)</sup> in which well documented clinical and radiographic data were available. The final diagnosis of BOOP was validated when patients presented.<sup>1</sup> In the recent Turkish study 58.9% patients had a smoking background. The association of smoking with organizing pneumonia has been controversial.<sup>4</sup>

In our study, 75% patients (19 out of 25) were having co-morbidities like Diabetes mellitus, Hypertension, Ischemic Heart Disease, Hypothyroidism, old Pulmonary Koch's, CKD and connective tissue disorders. All the deaths recorded had presence of one or more co-morbidities. There is no such study available for comparison.

Figure 4 and 5 shows distribution of co-morbidities in population.

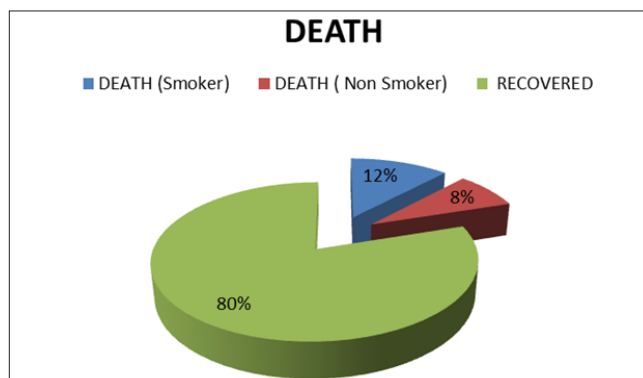


**Figure 4**



**Figure 5**

The mortality in our study was very high i.e. 20% (5 deaths). All the deaths were having co-morbidities and average age of death was 65 years (compared to average age of presentation i.e. 58 years). All these patients required ventilatory assistance and 60% of them were smokers. In total 28% (7 patients) required ventilator assistance.



**Figure 6. Showing percentage of deaths and smokers among them**

As observed in previous studies, rapid clinical deterioration was present in 21% subjects and 4% deaths were recorded in the study done by Cazzato S et al.<sup>3,8</sup>

Elderly population, Co-morbidity, smoking habit and ventilator support were observed as the high risk factors for the outcome of COP in our study group.

The Erythrocyte Sedimentation Rate was elevated in 80% of patients with a mean of 45mm/ hour.

**Radiological Analysis**

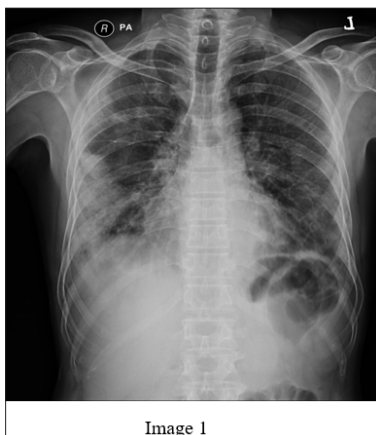The chest X-ray and the Computed Tomography scan findings of all the patients were described. The radiological findings were classified into unilateral or bilateral consolidations, reticulo-nodular opacity, multiple areas of nodularity in the lung parenchyma or nonspecific findings.

The common chest X-ray findings in our patient population were bilateral patchy consolidation noted in 36% (9 patients), unilateral consolidation in 24% (6 patients), reticulo-nodular opacities were seen in 8% patients and in 32% (8 patients) chest X-Ray was reported as normal. The Chest X-Ray findings in one of the previous studies by Sen et al were reticulo-nodular shadowing in 50% of patients, alveolar consolidations in 24% of patients and 18% of patients had a normal chest X-ray at presentation (3).

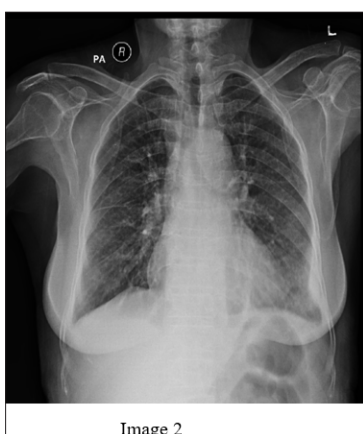- Ground Glass Opacities - 23 patients.
- Sub pleural and Interstitial Thickening - 12 patients.
- Multiple Nodular Enhancements - 07 patients.
- Cystic Changes and Traction Bronchiectasis - 08 patients.
- Others (Crazy paving, cavitary changes) - 02 patients.

**Table I. Showing HRCT lung findings**

| HRCT Findings                              | Frequency |
|--|-----------|
| Ground Glass Opacity                       | 23        |
| Sub pleural And Interstitial Thickening    | 12        |
| Multiple Nodular Enhancements              | 07        |
| Cystic Changes And Traction Bronchiectasis | 08        |
| Others                                     | 02        |

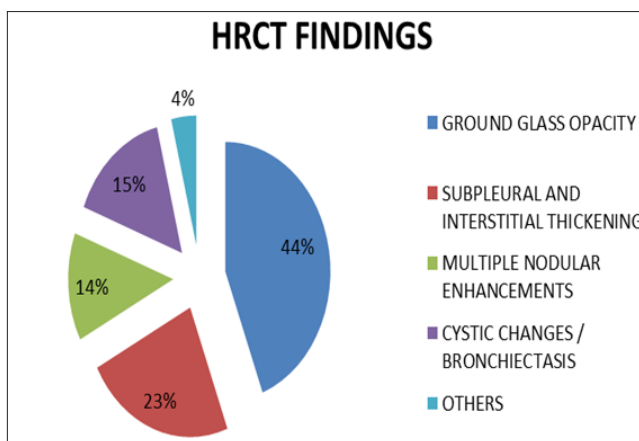


**Image 1. Chest X-Ray showing right mid and lower zone consolidation**

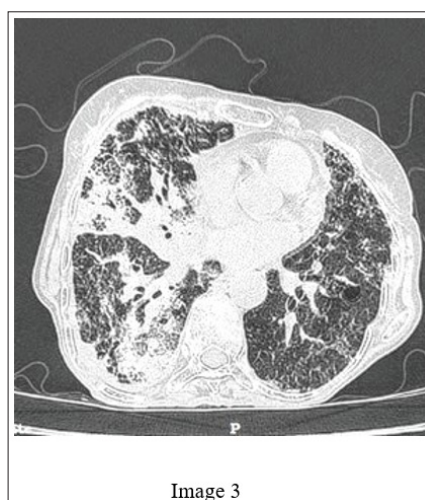


**Image 2. Chest X-Ray showing bilateral reticulo-nodular opacities**

High-Resolution Computed Tomographic (HRCT) scan of the chest was available in all patients and was very sensitive in detecting COP. In our study we divided HRCT findings under following headings:



**Figure 7. Distribution of findings on HRCT lung**



**Image 3. HRCT lung image showing patchy areas of consolidations seen mainly in right lung, mainly located in subpleural region and some extends in bronchovascular region. Areas of cavitation are seen in some of the lesions. Intra and interlobular septal thickening is seen mainly in subpleural region**

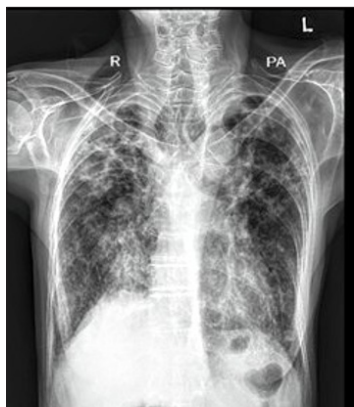

Image 4

**Image 4.A chest X-Ray film of same patient showing emphysematous changes with patchy areas of consolidation in bilateral upper zones**

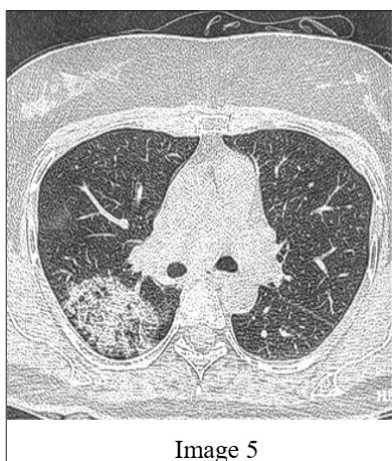


Image 5

**Image 5.An image of HRCT Lung showing patchy areas of ground glass opacities in right upper lobe with interstitial thickening**

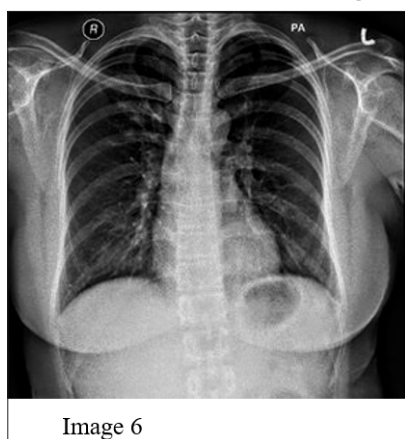


Image 6

**Image 6.A chest X-Ray image of the same patient showing no significant abnormality**

The study by Sen T et al. showed sub-pleural consolidation or peribronchovascular distribution in 56% of patients, ground glass infiltrates in 35% and the presence of nodules

in 9% patients.<sup>3</sup> In the study done by Baha a et al Bilateral symmetrical consolidations were observed as the most prominent radiological appearance.<sup>4</sup> All such patients before the confirmation of diagnosis were labelled as Non-Resolving Pneumonitis, Interstitial Lung Disease or Sputum negative Tuberculosis in these studies, which were subsequently confirmed histopathologic examination.

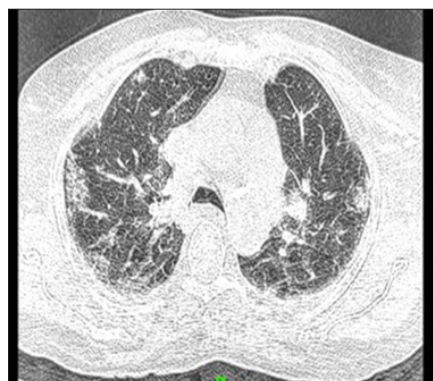

Image 7

**Image 7.HRCT lung image showing bilateral patchy consolidation in sub pleural region and associated with few nodules and mild septal thickening**

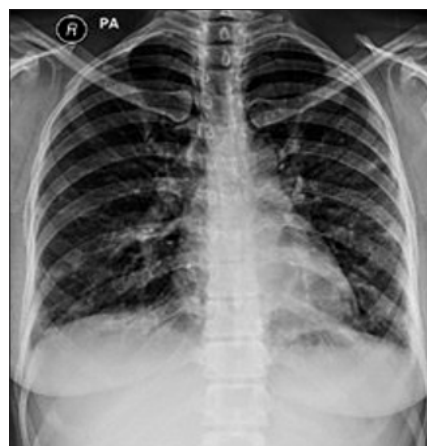

Image 8

**Image 8.A chest X-Ray image showing reticulo-nodular opacities in bilateral mid and lower zones**

With the advancement of Computed Tomography we could diagnose and treat the patients properly.

The limitation of our study and secondary data analysis was lack of invasive procedure like fiberoptic bronchoscopy and Histopathology of the lesions due to monetary constrains.

**Treatment**

Corticosteroid therapy is recommended for the treatment of COP. It is usually needed to be continued for at least 6 months due to its high rate of relapse.<sup>2</sup> In our study 48%

(12 out of 25) patients had received steroids. All patients received antibiotics during hospital stay. The antibiotics included penicillin, cephalosporin, macrolides, amino glycosides and quinolones. The antibiotics were used for short and long term. Almost all the patients received inhaled beta agonist and/ or corticosteroids, either for short or long period. The dose of steroids was titrated according to the need of the disease. The survivors (80% patients) were followed up and showed symptomatic and radiological improvement.

## Discussion

Cryptogenic Organizing Pneumonia (COP) is a clinicopathological entity which is a sub type of Interstitial Lung Disease (ILD).<sup>2</sup> It is defined histopathologically as granulation tissue plugs within the lumen of small airways, sometimes completely obstructing them, with granulation tissue extending into alveolar ducts and alveoli.<sup>1</sup>

The diagnosis of idiopathic COP is usually suggested by clinical suspicion, radiological findings and histopathological features. The desire to obtain surgical lung biopsy should be weighed against the risks which may include a short term mortality rate of nearly 5%.<sup>2</sup> In the patients with convincing clinical and radiographic presentation, in whom risks of an invasive procedure outweigh benefits, treatment can be started without a lung biopsy.<sup>9</sup>

Corticosteroid therapy is recommended for treating this condition. Recently there has been emerging evidence of the role of macrolides over a period of 3 to 12 months in the treatment of COP.<sup>10</sup> Our study provides insights into clinico-radiological presentations of COP.

The mean age of presentation in our case series was fifth decade. The clinical pattern of presentation included, breathlessness (72%), cough (68%), flu like symptoms (24%), chest pain (8%) and hemoptysis (1%). The study done by Udwadia ZF et al.<sup>3</sup> reported dry cough as the commonest presenting symptom, being present in 76% of the patients. This was followed by breathlessness in 65% of patients and sputum production in 35%. Fever and constitutional symptoms were present in 24% and 15% of patients respectively. Similar Findings were observed in the study done by Baha A et al. cough was the most common symptom (71.4%) followed by dyspnea (66.1%).<sup>4</sup>

In our study out of 25 patients 14 were male and 11 were females. All the other case series have reported increased incidence in female population. The common chest X-ray findings in our patient population were bilateral patchy consolidation noted in 36% (9 patients), unilateral consolidation in 24% (6 patients), reticulo-nodular opacities were seen in 8% patients and in 32% (8 patients) chest X-Ray was reported as normal. The Computed Tomography scan finding in our study showed presence of multiple ground

glass opacities as commonest findings (40%), whereas sub-pleural and interstitial thickening were noted in 23% cases. The study done by T. Sen and ZF Udwadia reported consolidation as the commonest feature (56%).<sup>3</sup> Baha A et al., in his study observed that Bilateral symmetrical consolidations were the most prominent radiological appearance.<sup>4</sup> The initial diagnosis of the patients based on clinical presentation and chest X-Ray findings were labeled as community acquired pneumonia, Interstitial lung disease and mycobacterial infections. Based on HRCT scan of lungs the findings became almost clear in favour of COP. This has practical importance in a developing country like India with a huge burden of bacterial pneumonia and mycobacterial diseases in the world. We could not confirm the diagnosis by lung biopsy. Awareness of the existence of a condition like COP even in this population of patients would be the first step to establishing correct diagnosis. In the other series published, the Diagnosis of COP was confirmed by Trans-bronchial lung biopsy. In our study all the patients received multiple courses of antibiotics in an attempt to cure them of their 'pneumonia'. The antibiotics included penicillin, cephalosporin, macrolides, amino glycosides and quinolones. 48% (12 out of 25) patients had received steroids. All patients received bronchodilators and inhaled corticosteroids. The dose of steroids was titrated according to the need of the disease. Apart from 20% (5) deaths, all (80%) patients responded to the treatment and showed symptomatic and radiological improvement.

There are very few similar studies done earlier. Clinical improvement as shown in the study of Sen T et al.<sup>3</sup> was seen in 71% cases, in Korean study<sup>11</sup> was 70% and in Italian study was 96%.<sup>8</sup>

Patients responding to the treatment showed intermittent exacerbations. The limitations of the present study were that Bronchoscopy and lung biopsy of the patients could not be done and serial pulmonary function of the patients could not be monitored due to monitoring constraints.

In summary we performed a critical review of 25 patients reported as COP which were clinically suspected and HRCT Lung reported cases. COP has varied clinical presentation with minimal radiological findings and florid Computed Tomographic findings. The non-responders may be subjected to invasive tests like bronchoscopy and lung biopsy. Pathological diagnosis is the final confirmation of diagnosis of COP. COP is a steroid responsive pathology. Most of our patients responded to antibiotics and steroids. The clinico-radiological response to steroids is in the range of 70% to 80%. Our study showed response rate of 80%, which falls within this range. The progressive nature of COP and late diagnosis may be the reasons for the lack of response and progressive clinical deterioration.

Table 2. Showing comparison of two studies

|                         | Indian Study<br>(Udwadia ZF et al.)                                    | Our Study   |
|-------------------------|--|---|
| Total Patients          | 34   | 25  |
| Presentation            | Cough, Dyspnoea,<br>Constitutional<br>Symptoms                         | Cough,<br>Dyspnoea, Flu<br>Like Symptoms  |
| HRCT Lung               | Sub-Pleural<br>Consolidation 56<br>%, Ground Glass<br>Opacities In 35% | Ground Glass<br>Opacities (44%),<br>Sub Pleural<br>And Interstitial<br>Thickening (28%) |
| Biopsy                  | 100%   | Not Done  |
| Clinical<br>Improvement | 71%  | 80%   |

## Conclusion

COP has varied clinical presentations and radiological spectrum. A high index of suspicion will lead to proper diagnosis and prompt treatment of such patients resulting in better patient outcome. The chronicity of the disease leads to long delay in diagnosis. There are chances of over diagnosing these patients as tuberculosis or atypical pneumonia, leading to delay in specific treatment. Role of early steroid therapy shows improvement in morbidity of these patients.

**Conflict of Interest:** None

## References

- Cordier JF. Cryptogenic organising pneumonia. *Eur Respir J* 2006; 28(2): 422-446. Available from: <https://erj.ersjournals.com/content/28/2/422.long> [PubMed/ Google Scholar].
- Jameson JL, Fauci AS, Kasper DL et al. Harrison's Principles of Internal Medicine. 20<sup>th</sup> ed. Jameson JL, editor. New York: McGrawHill Education; 2018. 1999-2008. Available from: <https://accessmedicine.mhmedical.com/book.aspx?bookID=2129>.
- Sen T, Udwadia ZF. Cryptogenic organizing pneumonia: Clinical profile in a series of 34 admitted patients in a hospital in India. *J Assoc Physicians India* 2008; 56: 229-232. [PubMed/ Google Scholar/ ResearchGate].
- Baha A, Yildirim F, Köktürk N, Galata Z, Akyürek N, Demirci NY et al. Cryptogenic and secondary organizing pneumonia: Clinical presentation, radiological and laboratory findings, treatment and prognosis in 56 cases. *Turkish Thorac J* 2018; 19(4): 201-208. [PubMed/ Google Scholar].
- Lee KS, Kullnig P, Hartman TE, Muller NL. Cryptogenic organizing pneumonia: CT findings in 43 patients. *Am J Roentgenol* 1994; 162(3): 543-546. Available from: <https://www.ajronline.org/doi/abs/10.2214/ajr.162.3.8109493> [PubMed/ Google Scholar]
- Worthy S. High resolution computed tomography of the lungs. *BMJ* 1995; 310(6980): 615-616. [PubMed].
- Cordier JF. Cryptogenic organizing pneumonia. *Clin Chest Med* 2004; 25(4): 727-738. Available from: <https://www.sciencedirect.com/science/article/abs/pii/S0272523104000656?via%3Dihub> [PubMed/ Google Scholar].
- Cazzato S, Zompatori M, Baruzzi G, Schiattone ML, Burzi M, Rossi A et al. Bronchiolitis obliterans-organizing pneumonia: An Italian experience. *Respir Med* 2000; 94(7): 702-708. Available from: [https://www.resmedjournal.com/article/S0954-6111\(00\)90805-9/pdf](https://www.resmedjournal.com/article/S0954-6111(00)90805-9/pdf) [PubMed/ Google Scholar].
- Chandra, Deepak; Hershberger DM. Cryptogenic Organizing Pneumonia. *StatPearls Publ* [Internet]. 2019. Available from: <https://www.ncbi.nlm.nih.gov/books/NBK507874/?report=classic>.
- Pathak V, Kuhn JM, Durham C, Funkhouser WK, Henke DC. Macrolide use leads to clinical and radiological improvement in patients with cryptogenic organizing pneumonia. *Ann Am Thorac Soc* 2014; 11(1): 87-91. Available from: [https://www.atsjournals.org/doi/full/10.1513/AnnalsATS.201308-261CR?url\\_ver=Z39.88-2003&rfr\\_id=ori%3Arid%3Acrossref.org&rfr\\_dat=cr\\_pub%3Dpubmed](https://www.atsjournals.org/doi/full/10.1513/AnnalsATS.201308-261CR?url_ver=Z39.88-2003&rfr_id=ori%3Arid%3Acrossref.org&rfr_dat=cr_pub%3Dpubmed) [PubMed/ Google Scholar].
- Han SK, Yim JJ, Lee JH, Yoo CG, Chung HS, Shim YS et al. Bronchiolitis obliterans organizing pneumonia in Korea. *Respirology* 1998; 3(3): 187-191. Available from: <https://onlinelibrary.wiley.com/doi/abs/10.1111/j.1440-1843.1998.tb00119.x?sid=nlm%3Apubmed> [PubMed/ Google Scholar].