

Research Article

Survival of 21 Dogs after Post-exposure Prophylaxis using Intra-dermal Rabies Vaccine in the Pre-scapular Region and Emergency Use of Expired Equine Rabies Immunoglobulin for Local Wound Infiltration in Victims of a Rabid Dog Bite using One Health Approach

*Anil Kumar Sharma*¹, *Omesh Kumar Bharti*², *Vinay Chavan Prakash*³, *Dilip Lakshman*³,
*Shrikrishna Isloor*³, *Ashok Kumar Panda*⁴, *Jyotsna Sharma*⁵

¹Department of Animal Husbandry, Govt of Himachal Pradesh, India.

²Department of Health and Family Welfare, Govt of Himachal Pradesh, India.

³Veterinary College, KVAFSU, Hebbal, Bangalore, India.

⁴Department of Veterinary Public Health, CSKHPKV, Palampur, Himachal Pradesh, India.

⁵Department of Ayush, Govt of Himachal Pradesh, India.

DOI: <https://doi.org/10.24321/2455.7048.202215>

I N F O

Corresponding Author:

Anil Kumar Sharma, Department of Animal Husbandry, Govt of Himachal Pradesh, India.

E-mail Id:

Sharmaisanil6@gmail.com

Orcid Id:

<https://orcid.org/0000-0002-6578-7364>

How to cite this article:

Sharma AK, Bharti OK, Prakash VC, Lakshman D, Isloor S, Panda AK, Sharma J. Survival of 21 Dogs after Post-exposure Prophylaxis using Intra-dermal Rabies Vaccine in the Pre-scapular Region and Emergency Use of Expired Equine Rabies Immunoglobulin for Local Wound Infiltration in Victims of a Rabid Dog Bite using One Health Approach. *Epidem Int.* 2022;7(4):12-18.

Date of Submission: 2022-12-15

Date of Acceptance: 2022-12-30

A B S T R A C T

Rabies is a 100% fatal zoonotic disease and is preventable through timely and adequate Post-Exposure Prophylaxis (PEP). World Organization for Animal Health (WOAH) haven't issued any guidelines for PEP for rabies in animals, still in certain Indian states like Himachal Pradesh (HP) PEP regimen with active immunization on 0,3,7,14 and 28 days mostly by Intramuscular Rabies Vaccine (IMRV) is being followed. Recently in Rampur Bushahar, a suspected rabid dog later laboratory confirmed had bitten 21 dogs, 2 cows, and 2 men. We employed PEP in animals using Raksharab vaccine intra-dermally (IDRV) (0.2 ml, pre-scapular region) on days 0, 3, 7, 14, and 28 along with only local wound infiltration of eRIG in 8 out of 11 bitten dogs with Category III exposure. Furthermore, 3 noncooperative dogs with Category III exposure were given IMRV (1ml) on day 0,3,7,14,28 with only wound infiltration of eRIG. 2 Cows were administered 0.2 ml IDRV in the skin at the middle of the neck with only wound infiltration of eRIG. Human bite victims also received 0.1 ml IDRV at 2 sites in the deltoid region on days 0,3, and 7 along with wound infiltration of eRIG at the nearby health center. Serum samples were collected for Rapid Fluorescent Focus Inhibition Test (RFFIT) for estimation of Rabies Vaccine Neutralizing Antibody (RVNA) titer after day 14 for 8 dogs, 2 cows, and human bite victims, and all had RVNA titer >0.5 IU/ml on day 14 except one in IMRV group. None of the bitten

victims had clinical manifestations of rabies even after 1 year of follow-up. This indicates wound infiltration with eRIG along with the vaccine could be a life-saving protocol. Also using expired eRIG in emergencies was safe and life saving in animals. Expired eRIG used was later tested and was found to be potent.

Keywords: Rabies, eRIG, Intra-dermal Rabies Vaccination, Local Wound Infiltration, Post Exposure Prophylaxis in Animals, India

Introduction

Rabies, caused by lyssaviruses, is a zoonotic disease responsible for an estimated 59,000 human deaths per year and is classified as a neglected zoonotic disease by the World Health Organization (WHO). Of this, 36% of the disease burden can be seen in India alone accounting for 20,000 human deaths every year.¹ There is no cure for rabies but it is almost 100% preventable by timely and proper rabies PEP.

The disease is transmitted by rabid animals mainly dogs following the bite, lick on a wound/ scratch, or on abraded skin or mucous membrane of the individual. Commonly, rabies is transmitted following the bite of a rabid dog (97%), cat (2%), and other animals (1%) i.e. mongoose, fox, wolf,

jackal, and other wild animals.² There are approximately 35 million stray dogs in India.³ In Himachal Pradesh, human rabies deaths due to mongoose bites have been reported in Kangra district of Himachal Pradesh and mongoose were found positive for rabies virus.⁴

Materials and Methods

Ethics Statement

Institutional Animal Ethics Committee (IAEC) approval was obtained from COVAS, CSKHPKV Palampur (No.COVAS/IAEC/2021-14) for blood sampling, IDRV, and using near expiry/expiry eRIG for emergency PEP in animals as eRIG for animal use is not available.

Study Area

Rampur Bushahar (Latitude of 31.4492° N, and Longitude 77.6298° E), a tehsil in upper Shimla region of Himachal Pradesh in Northern India, has a human population of 77,542 (Census, 2011).

Living Subjects (Animals/ Human)

A rabid dog (confirmed rabid based on FAT at CRI, Kasauli) had bitten 21 dogs, 2 cows, and 2 men in Rampur Bushahar, Himachal Pradesh and all were given PEP and followed up for survival and serum samples collected for titers (Table 1).

Table 1. Description of Animals and Humans Included

Species	No. of Animals/ Human Bitten	Category of Wound	PEP Followed	Site and Volume of Vaccine used on Days 0,3,7,14 and 28
Bovine	2	Category III	IDRV + eRIG	Middle of the neck 0.2ml
Canine	21	10 had Category II exposure	ARV only	Prescapular region 0.2 ml IDRV
		11 had Category III exposure	8 dogs given IDRV+eRIG (local infiltration)	0.2 ml at prescapular region
			3dogs given IMRV+eRIG (local infiltration)	1ml at biceps femoris muscle
Human	2	Category III	IDRV +eRIG (local infiltration) given PEP at PHC by Medical clinicians	0.1 ml in 2 sites near deltoid region on days 0,3 and 7 (IPC Regimen)

Vaccine

The vaccine used in animals was Inj. Raksharab manufactured and marketed by Indian Immunologicals Ltd., (Batch no. 01RAB03520 MNF12/20 EXP11/23) in which each ml contains inactivated rabies viral antigen of potency ≥ 2.5 IU rabies virus stain CVS propagated on BHK cells adsorbed on the aluminum hydroxide gel, thiomersal

I.P. as preservative $\leq 0.02\%$ w/v and Phosphate buffer diluents q.s. to 1 ml.

eRIG

Use of expired medicine in emergency is not uncommon in medical practice. Recently in a study anti-snake venom was potent even after 20 years of its expiry and have the potential for use in an emergency to save lives.⁵ Another

study also has shown that antibodies are forever and have a tendency to have workable half life upto 10 years.⁶ Based on such studies by Argentiieri et al, we had kept some expired eRIG for titers testing so as to use in animal PEP as practice in some Himachal Vet clinics⁴, but we have to use this expired eRIG in emergency when a suspected rabid dog had bitten 21 dogs and 2 cows that proved its efficacy on further testing. Moreover, we need more than 0.5 IU/ml titers of eRIG for only wound infiltration, which was supposed to be there even if eRIG was expired.⁷ One human being was given due vaccine and eRIG that was not expired.

We infiltrated the local bite wounds with category III exposure with expired eRIG available with us in animals, which was procured from nearby health facility. The 5 months expired eRIG was used in an emergency (clearance for the same was obtained from IAEC in emergency). Later on we tested the potency of this expired eRIG on 10/03/2022 at about 7 months from Date of Expiry at KVAFSU-CVA Rabies Diagnostic Laboratory, Veterinary College, Bengaluru and it was found fully potent at required 300 IU/ml.

All animal bite victims were administered with the same batch of eRIG (batch no. 02AR19002 / MFG08/2019, EXP-07/2021) manufactured by ViNS Bioproducts Ltd., Telangana, India. Wound site was locally infiltrated with eRIG as per published “Madhusudana-Bharti-Uppinder” protocol.⁸ In human beings, eRIG used was administered from government supply available in PHC-Rampur of potency 300 IU/ml (Batch no. 02-AR00007 Exp. August 2022 manufactured by ViNS Bioproducts limited) and wounds were infiltrated as per latest WHO guidelines 2018.⁹

Procedure/ Technique for Intra-dermal Vaccination and eRIG Infiltration

This involved administration of 0.2 ml of rabies vaccine Intradermal (ID) on the pre-scapular region in dogs and in the middle of the neck in lateral side of the cattle. Using an aseptic technique, 1 ml insulin syringe, 0.2 ml (up to 8 units in a 40 unit insulin syringe; i.e. 0.2 ml per ID site) of vaccine was injected into the dermal layer of skin. Insulin syringe was brought parallel to the skin making about 10° angle, after insertion of 30% portion of the insulin syringe vaccine was administered. A raised bleb about 1 cm diameter appeared immediately (Figure 1, Figure 3). While in the IM group, vaccine was administered in biceps femoris muscle in dogs. Furthermore, eRIG was infiltrated into the wounds directly by superficial and deep administration into the wound site so as to cover the entire wound surface till the depth of the wound, to ensure complete virus neutralization on the surface of the wound/s (Figure 2 and Figure 4).



Figure 1.IDRV 0.2 ml in Pre-scapular Region in a Dog Bitten by Lab. Confirmed Rabid Dog



Figure 2 : Local wound infiltration with eRIG in a dog bitten by rabid dog.



Figure 3.IDRV 0.2 ml in Middle of the Neck in a Cow Bitten by Rabid Dog



Figure 4. Local Wound Infiltration with eRIG in a Cow Bitten by Lab Confirmed Rabid Dog

Blood Sampling

Out of 21 dogs, 2 cows and 2 men; 11 severely bitten dogs, 2 cows and one man with category III exposure available for blood sampling were selected for estimating the Rabies Virus Neutralizing Antibodies (RVNA) as all were bitten by the same rabid dog.

Blood samples were collected on day 14 after initiation of PEP. Approximately 2-5 mL of blood was collected via cephalic vein in animals and via cubital vein in the man using sterile syringe and then transferred to sterile vacutainers.

After collection, blood samples were allowed to settle for 1-2 hours and then centrifuged at 2000 rpm for 15 minutes. The serum collected was stored in corked serum vials in -20 degree Celsius in VPC-Rampur for about a week and serum samples were then transported to the KVAFSU-CVA rabies diagnostic laboratory, Veterinary college, KVAFSU, Hebbal Bengaluru in cold chain for RVNA testing by RFFIT.

Rapid Fluorescent Focus Inhibition Test (RFFIT)

RFFIT for estimation of RVNA was performed at the KVAFSU-CVA Rabies diagnostic laboratory, Veterinary College, KVAFSU, Hebbal, Bengaluru, using a WHO recommended procedure with minor modifications (Smith et al., 1996).¹⁰ BHK-21 cell line (ATCC CCL 10) and BHK-21 adapted CVS 11 strain of virus were used and the tests were performed in 96 well tissue culture plates. The antibody titers were expressed in International units (IU/ml) in comparison to an in-house reference serum calibrated against 2nd International reference serum obtained from the National Institute of Biological Standards, UK.

Results

Results show that PEP using the ID route of vaccination in animals had RVNA titer >0.5 IU/ml on day 14 but in the IM group results were variable with one dog having RVNA titers < 0.5 IU/ml in this group on day 14. The average volume of eRIG used in these bite cases was 2.5 ml. Details are given in Table 2.

Table 2. RFFIT Results and Victim Animal Followed up to 1 Year

Patient ID-species	Age (yr)/ Body weight (Kgs)	Delay in bringing the patient to VPC	Wound Site	Bitten by	Volume of locally infiltrated RIG used	Day of Blood Sample	RFFIT titre (IU/ml)	Biting animal follow-up (Dog)	Patient animal followed up to 1 year
ID-180-D14 Cow	7y/350kg	0	Muzzle and Nose	Rabid Dog	4ml	14	2	Died on 4 th day after biting	Alive
ID-183-D14 Cow	8y/ 320 kg	1day	Muzzle, lips and nose	Rabid Dog	5ml	14	4	Do	Died due to non rabid reasons
IM-179-D14 dog	10yr/40kg	0	Front legs	Rabid Dog	0.7ml	14	<0.5	Do	Alive
ID-181-D14 dog	1.5m/3kg	1day	Eye and mandible	Rabid Dog	3ml	14	0.5	Do	Alive
ID-184-D14 dog	1yr/35kg	2days	Ear and right foreleg	Rabid Dog	1.2ml	14	2	Do	Alive

ID-185-D14 dog	1yr/26kg	2days	Shoulder	Rabid Dog	2ml	14	2	Do	Alive
ID-186-D14 dog	2yr/25kg	2days	Left Hind legs	Rabid Dog	10ml	14	1	Do	Alive
ID-187-D14 dog	7m/11kg	2days	Right foreleg	Rabid Dog	0.7ml	14	4	Do	Alive
ID-189-D14 dog	8yr/13kg	1day	Both hind legs	Rabid Dog	2.6ml	14	2	Do	Alive
ID-192-D14 dog	4m/6kg	1day	Back	Rabid Dog	0.8ml	14	NA	Do	Alive
IM-193-D14 dog	5y/20kg	1day	Leg	Rabid Dog	0.9ml	14	8	Do	Alive
IM-194-D14 dog	7y/21kg	1day	Leg	Rabid Dog	1ml	14	NA	Do	Alive
ID-195A-D14 dog	7y/16kg	0	Hind limbs	Rabid Dog	1.5ml	14	NA	Do	Alive
ID-D14-Ravi	38y/72kg	0	Right leg	Rabid Dog	4 ml	14	4	Do	Alive

Discussion

WOAH has not provided any kind of guidelines regarding PEP in animals when exposed to rabies infected animals even for rabies endemic regions like Asia and Africa and only PrEP is recommended. In the present Indian scenario, not all domestic animals are getting PrEP against rabies, only a small percentage of pet owners are going for it in urban areas of the country. It is observed that in most of the cases, animal bite victims fall under category III bites which require the administration of anti-rabies serum as well which is available only for passive immunization in humans. IM rabies vaccine in animals has shown protective effect¹¹ but still, PEP failures have been reported.¹² Even vaccine antigen titers when raised to 4 I.U./ml are reported to result in failure.¹³ Only Intra-dermal rabies vaccination without RIG infiltration has shown its efficacy in limited studies in cattle.¹⁴ However, there are limited studies on IDRV with eRIG local wound infiltration in animals.⁴ One time intradermal DNA vaccine in ear pinnae one year prior to exposure had shown a lasting immunity for more than a year.¹⁵ It is usual that many livestock animals are bitten by dogs and wild animals which may be unnoticed in rural settings and livestock owners recognize rabies once clinical symptoms are observed after a few weeks of biting by rabid animals. Unless the administration of eRIG at the site of a bite along with PEP is practiced in animal bite victims, there is always the risk of having rabies in vaccinated animals often creating a false sense of security.

We performed local wound infiltration according to the size of the wound. Infiltration of 3ml eRIG was done in a

pup (ID181D14 dog, Table 2) weighing 3 Kgs only and no side effects were observed in the pup. Similarly in a dog weighing 22 Kgs, 10 ml eRIG was infiltrated locally (Table 2). This indicates eRIG infiltration based on body weight does not carry any meaning and also excess eRIG administered does not interfere with the vaccine response.

All animals bitten i.e. dogs, cows, and 2 humans were safe except one cow that died due to non-rabid reasons based on clinical investigation, so far even after one year of episodes, none of the bitten victims have shown any clinical manifestations of rabies.

A rabid dog is considered to transmit rabies to at least 30% of bitten animals or humans if no PEP is given due to the intermittent release of the virus in the saliva of a rabid dog, even PEP failures are there when animals receive vaccines through IM route (without eRIG). But in our study, we used the ID route and local wound infiltration with eRIG which has proven to be more immunogenic. This indicates local wound infiltration with eRIG along with the anti-rabies vaccination, could be life-saving for animals too, which actually acts as the source of further rabies spread especially dogs in India. It can be seen in Figure-5, a passive zone of protection is formed in the first 7 days by infiltrating eRIG. As the vaccine takes about 7 to 14 days to achieve the immunogenic effect by active immunization, it can be concluded that local administration of RIG is a must to save the life, if the animal is bitten by a rabies-confirmed dog and has not been previously vaccinated. This study suggested practicing local wound infiltration with eRIG on the bite site and ID vaccination of 0.2 ml in the pre-scapular region

in dogs and in the middle of the neck in cows on days 0, 3, 7, 14 and 28 for PEP against rabies in animals life-saving.

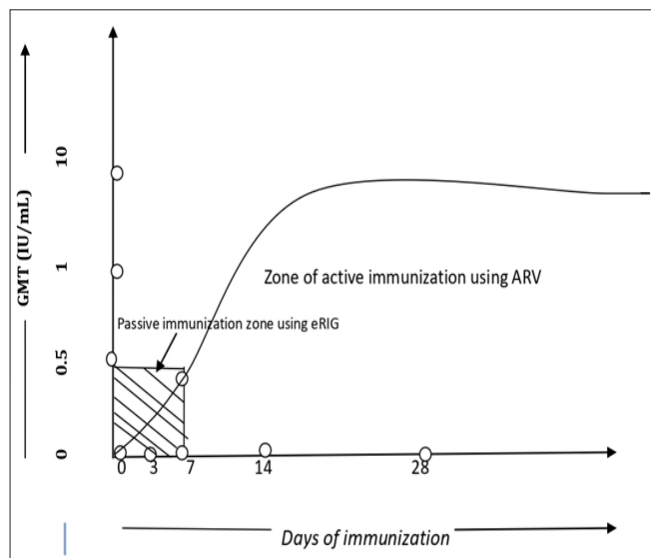


Figure 5: Immunization curve showing protective zone through RIG administration.

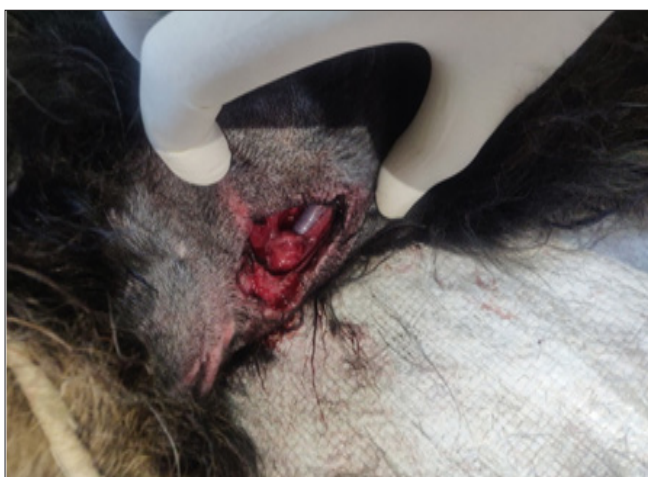

Figure 6. Category III Exposure Jugular Vein Exposed - Infiltration with RIG is must for these Kinds of Wounds

Anti rabies vaccination through ID regime has more immunogenic effect as it is administered directly in the dermis layer and it gets drained to dendritic cells and thus inducing a greater or at least equal immune response with five times less dosage. One dose of Inj. Raksharab costs around 2 USD (150 INR) if given intramuscularly, and 0.4 USD (30 INR) if given by ID route. So, PEP by IDRV is cost as well as dose sparing and more immunogenic as compared with the IM route.

Conclusions

This study is suggestive of practicing local wound infiltration with eRIG on the bite site and IDRV 0.2 ml in the pre-scapular region in dogs and in the middle of the neck in cows

on days 0, 3, 7, 14, and 28 for PEP is life-saving in animals. The total volume of ARV used in IDRV PEP regime will be 1 ml (0.2 ml each dose) and at present, we are following IMRV which requires 5 ml of ARV (1 ml each dose). This makes IDRV more cost-effective (80%) and can be easily made available in government institutions too in near future. This may clear the hurdle of the financial burden on the farmer/pet owner. Another factor that goes in favor of IDRV is less or almost no pain to fine needle insulin syringe compared to stressful response to IM vaccination in animals.

Recommendations

We recommend veterinarians of countries including India where rabies is endemic to follow this low cost and high immunogenic protocol of ID anti rabies vaccination with local eRIG wound infiltration for PEP of dogs, bovines or other domestic animals like feline, equine, ovine, and caprine. We also recommend veterinary vaccine companies label rabies vaccines as "ID/IM" use like human vaccines to facilitate this process for wider pre-exposure use that would make them cost-effective for poor farmers in rabies-endemic countries of Asia and Africa.

One of the concerns about using eRIG / RIG in animals for PEP is its short supply for human bite victims, hence using the "one health" concept we propose that instead of destroying expired eRIG in hospitals and production centers like CRI Kasauli, we give it for animal use so as to use expired eRIG for animals PEP after due titers testing.

Source of Funding: None

Conflict of Interest: None

Acknowledgements

We are sincerely grateful to the staff of KVAFSU-CVA rabies diagnosis laboratory, Bengaluru, India for carrying out RFFIT, and CRI Kasauli, Himachal for FAT test on animal's brain sample free of cost.

References

1. WHO Expert Consultation on Rabies. Third report; 2017. [Google Scholar]
2. Isloor S, Marissen WE, Veeresh BH, Nithinprabhu K, Kuzmin IV, Ruprecht CE, Satyanarayana ML, Deepti BR, Sharada R, Neelufer MS, Yathiraj S, Abdul RS. First case report of rabies in a wolf (*Canis Lupus Pallipes*) from India. *J Vet Med Res.* 2014;1(3):1012. [Google Scholar]
3. Times of India [Internet]. 6 facts about stray dogs in India; 2022;5. Available from: <https://timesofindia.indiatimes.com/life-style/relationships/pets/6-facts-about-stray-dogs-in-india/photostory/89346302.cms>
4. Bharti OK, Sharma UK, Kumar A, Phull A. Exploring the feasibility of a new low cost intra-dermal pre & post exposure rabies prophylaxis protocol in domestic bovine in Jawali Veterinary Hospital, District Kangra,

- Himachal Pradesh, India. *World J Vaccines*. 2018;8(1). [Google Scholar]
5. Sánchez EE, Migl C, Suntravat M, Rodriguez-Acosta A, Galan JA, Salazar E. The neutralization efficacy of expired polyvalent antivenoms: an alternative option. *Toxicon*. 2019;168:32-9. [PubMed] [Google Scholar]
 6. Argentieri MC, Pilla D, Vanzati A, Lonardi S, Facchetti F, Doglioni C, Parravicini C, Cattoretti G. Antibodies are forever: a study using 12-26-year-old expired antibodies. *Histopathology*. 2013;63(6):869-76. [PubMed] [Google Scholar]
 7. Bharti OK, Anderson DC, Kishore J, Katoch P, Sharma P. Small Volume of Rabies Immunoglobulin (RIG) is effective for local wound infiltration in Rabies Post-Exposure Prophylaxis whereas intramuscular RIG is just a wastage. *J Adv Res Med*. 2021;8(3):8-12. [Google Scholar]
 8. Bharti OK, Kumar Sharma U, Kumar A, Phull A. Exploring the feasibility of a new low cost intra-dermal pre & post exposure rabies prophylaxis protocol in domestic bovine in Jawali Veterinary Hospital, District Kangra, Himachal Pradesh, India. *World J Vaccines*. 2018;8:8-20. [Google Scholar]
 9. Rabies vaccines and immunoglobulins: WHO position April 2018. <https://www.who.int/publications/i/item/WHO-TRS-1012>
 10. Smith JS, Yager PA, Baer GM. A rapid fluorescent focus inhibition test for determining rabies virus neutralizing antibody. In: Meslin FX, Kaplan MM, Koprowski H, editors. *Laboratory techniques in rabies*. 4th ed. Geneva: WHO. 1996;181-7. [Google Scholar]
 11. Basheer AM, Ramakrishna J, Manickam R. Evaluation of post-exposure vaccination against rabies in cattle. *New Microbiol*. 1997;20:289-94. [PubMed] [Google Scholar]
 12. Sunilkumar KM, Isloor S, Kamran CA, Santosh AK, Ramesh PT, Sharada R, Yathiraj S, Rathnamma D, Suryanarayana T, Patil SS, Patil A. Sero monitoring of anti rabies vaccinal neutralizing antibodies to PEP in animals by RFFIT - a case study in Karnataka. *J Exp Biol Agri Sci*. 2016;4(Spl-3-ADPCIAD):S103-7. [Google Scholar]
 13. Wilson PJ, Clark KA. Postexposure rabies prophylaxis protocol for domestic animals and epidemiologic characteristics of rabies vaccination failures in Texas: 1995-1999. *J Am Vet Med Assoc*. 2001;218(4):522-5. [PubMed] [Google Scholar]
 14. Beníšek Z, Suli J, Švrček Š, Ondřejková A, Mojzisoava J, Ondřejka R. Intradermal anti-rabies immunization - possibilities of needleless rabies vaccine administration. *Bull Vet Inst Pulawy*. 2006;50(2):137-42. [Google Scholar]
 15. Lodmell DL, Ewalt LC, Parnell MJ, Rupprecht CE, Hanlon CA. One-time intradermal DNA vaccination in ear pinnae one year prior to infection protects dogs against rabies virus. *Vaccine*. 2006;24(4):412-6. [PubMed] [Google Scholar]