

Case Study

Fabrication of Gasket Retained Cu-Sil Like Partial Denture Using 3D Printed Technology in the Rehabilitation of Patient with Single Remaining Natural Teeth – A Case Report

Surya Rengasamy¹, Vidyashree Nandini V², Shiney Boruah³

¹Reader, ²Professor & HOD, ³Senior Lecturer, Department of Prosthodontics & Implantology, SRM Kattankulathur Dental College & Hospital, SRM Institute of Science & Technology, India.

DOI: <https://doi.org/10.24321/2278.2044.202471>

I N F O

Corresponding Author:

Vidyashree Nandini V, Department of Prosthodontics & Implantology, SRM Kattankulathur Dental College & Hospital, SRM Institute of Science & Technology, India.

E-mail Id:

vidyashv@srmist.edu.in

Orcid Id:

<https://orcid.org/0000-0002-4439-7957>

How to cite this article:

Rengasamy S, Nandini V V, Boruah S. Fabrication of Gasket Retained Cu-Sil Like Partial Denture Using 3D Printed Technology in the Rehabilitation of Patient with Single Remaining Natural Teeth – A Case Report. Chettinad Health City Med J. 2024;13(4):146-149.

Date of Submission: 2023-08-03

Date of Acceptance: 2024-01-22

A B S T R A C T

This case report describes a novel technique of fabrication of gasket retained Cu-sil partial denture for a patient with a single tooth remaining in the maxillary arch. A gasket ring of Cu-sil was fabricated using 3D printing technology with polyurethane material using the fused deposition modelling technique. The denture was processed with the 3D printed gasket ring in the conventional manner using heat cure acrylic resin. This technique helped in providing accurate fit and retention for the prosthesis while retaining the natural teeth.

Keywords: Cu-Sil Denture, Partial Denture, Transitional Denture, 3D Printing, Additive Technology

Introduction

Preventive prosthodontics is one of the areas of prosthodontics which is gaining importance. Preventive prosthodontics aims at preserving and protecting the remaining tissues to provide long-term function of the prosthesis and limit the disability in the future.¹ Protecting and preserving the remaining teeth becomes important especially when few teeth are remaining. This ensures the alveolar bone is preserved and proprioception is maintained.

It also gives a psychological benefit to the patient.^{2,3} The treatment options for rehabilitation of patients with few remaining teeth include overdentures, transitional dentures and immediate dentures following extraction of the remaining teeth. Overdentures have the advantage of preserving the alveolar bone and proprioception but require additional visits and costs for endodontic treatment of abutment teeth.⁴⁻⁶ Immediate dentures require the extraction of the remaining natural teeth which might cause psychological trauma to the patient and also requires the

fabrication of new dentures after 3–6 months because of the resorption after extraction.⁴ Gasket retained Cu-sil transitional denture is one of the best options available with the advantage of retaining the teeth for retention and preservation of the tissues.

Cu-Sil® was first commercially marketed as an alternative option for overdentures and conventional complete dentures in patients with few remaining natural teeth. They provided the advantages of providing retention and cushioning effect to the abutment teeth reducing the stress to abutment teeth. It also provides a seal around the teeth preventing leakage of food and fluids.⁷ From then on, clinically similar Cu-sil-like dentures were fabricated for patients with few teeth as a form of transitional denture. The flexible gaskets were either stock silicone rings or the dentures were lined in the abutment area with acrylic-based or silicone liners to form the gasket.^{8–19}

This case report describes the use of a gasket-retained Cu-sil partial denture to rehabilitate a patient with a single tooth remaining in the maxillary arch. This a novel technique wherein additive technology is utilised in fabricating the resilient gasket ring around the tooth.

Case Report

A 71-year-old male patient reported to the Department of Prosthodontics & Implantology, SRM Kattankulathur Dental College and Hospital with the chief complaint of missing teeth in the upper and lower arch. On intraoral examination, the patient presented with only one tooth remaining (13) which was periodontally sound with no mobility (Figure 1).

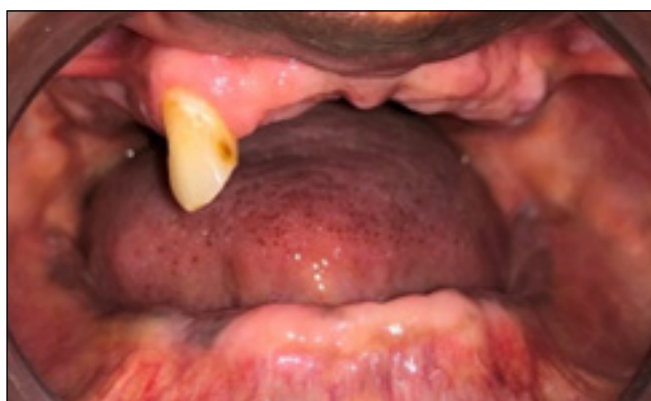

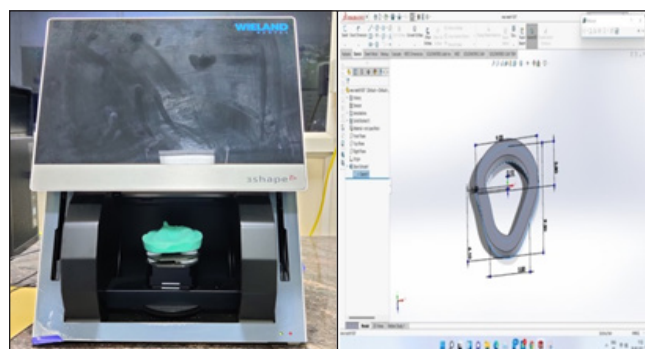
Figure 1. Presence of A Single Natural Tooth¹³

The patient was explained about the treatment options for rehabilitation. The options for maxilla include overdenture after endodontic treatment and preparation of 13; extraction of 13 followed by fabrication of immediate complete denture in the maxillary arch; and a gasket retained acrylic transitional partial denture in the maxilla. The patient was explained about the advantages and disadvantages of each option and the importance of retaining teeth to

preserve the remaining bone was also emphasised. The patient agreed to proceed with the fabrication of gasket retained partial denture retaining 13 in the maxilla and a complete denture in the mandible. The treatment plan involved the fabrication of the gasket for the Cu-sil denture using 3D printing technology.

Steps in Fabrication of Gasket Retained Cu-Sil Acrylic Partial Denture

1. Maxillary primary impression was made using irreversible hydrocolloid (Tropicalgin, Zhermack, India) and a custom try was fabricated after providing an extra spacer for 13. The final impression was made using an additional silicone impression material (Aquasil, Dentsply, India) and a master cast was obtained.
2. The master cast was scanned using a model scanner (D900 L, 3 Shape, Denmark) (Figure 2a) and designing was done with CAD software (CATIA V-5 software, Dassault systems, France).
3. The gasket ring was designed around the cervical region of 13 with a thickness of 2 mm and the stereolithographic file was sent to the 3D printing unit (Figure 2b).
4. 3D printing was done by the fused deposition modelling technique (Ultimaker 3P03, IMIK, Netherlands) with a nozzle thickness of 0.2 mm using thermoplastic polyurethane.
5. Jaw relation and wax try-in were done following the conventional procedure for complete denture fabrication.
6. The printed ring was placed over the cervical region of 13 in the master cast and wax up of the trial denture was completed. The denture was processed using heat cure acrylic resin (DPI Heat cure Resin, DPI, India) (Figure 3).
7. The processed denture had the gasket ring incorporated around the cervical region of 13 (Figure 4). The denture was inserted in the patient's mouth and evaluated (Figure 5). Post-insertion instructions were given and the patient was recalled for regular review. The patient was reviewed after a 2-year follow-up. Clinical and radiographic examination revealed healthy 13 (Figure 6) with minimal damage and wear of the gasket ring.



**Figure 2(a). Scanning of the Maxillary Cast
(b). Designing of the Gasket Ring**

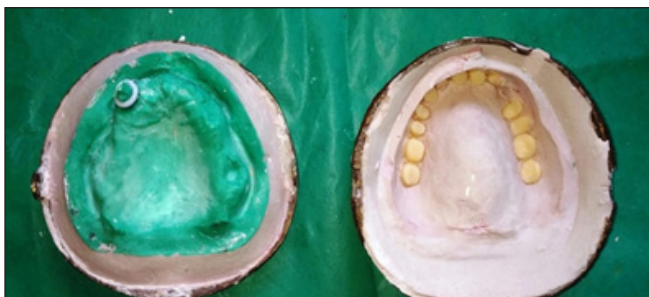

Figure 3. 3D-Printed TPU Ring Fitted on 13 Before Packing

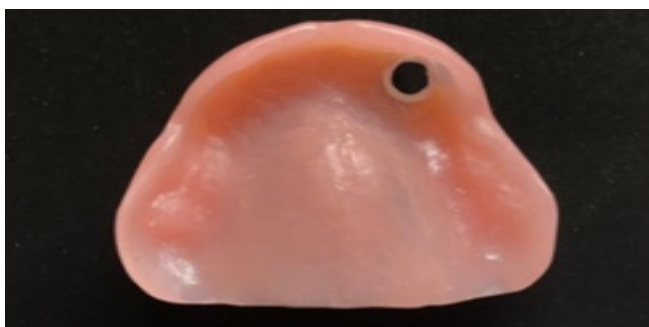

Figure 4. Processed Maxillary Denture with the Gasket

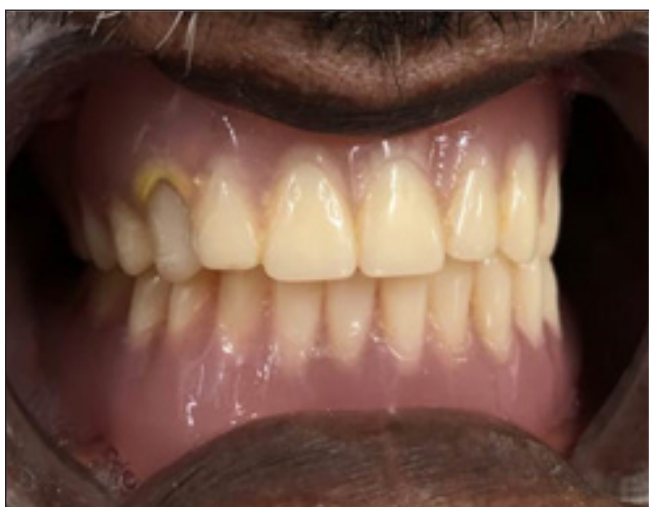

Figure 5. Intraoral View of the Final Dentures

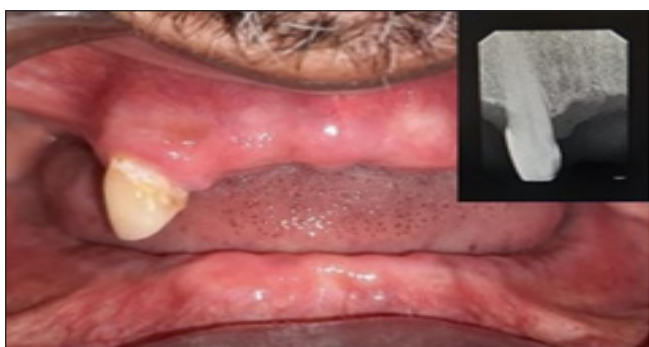


Figure 6. Clinical Picture and Radiograph of 13 After 2-Year Follow-Up

Discussion

Preventive prosthodontics involves the preservation of remaining oral structures to preserve for the future and reduce the disability. In this case, preserving the remaining tooth was chosen to preserve the alveolar bone and proprioception and also provide retention for the denture.¹ Gasket retained Cu-sil denture is an acrylic transitional prosthesis with a soft resilient gasket encircling the cervical neck of the remaining natural tooth. This gasket seals out the food and fluids; provides a cushioning effect and also retention to the denture.⁷ This was chosen as a viable option for this case since 13 was periodontally sound and the patient preferred to retain the teeth and proceed with the treatment.

Using 3D printing technology to fabricate the resilient gasket will provide a more accurate adaptation of the ring around the natural teeth. Previous techniques described in the literature either used stock silicone rings or silicone soft liners for this type of denture. The use of stock silicone rings had the disadvantage of limited size availability and also needed adjustment to be fitted. In the case of lining technique, after the denture is processed, space is created for the lining material around the tooth and pickup of the soft liner is done intraorally during the insertion procedure.⁸⁻¹⁹

In this technique, the gasket was made of thermoplastic polyurethane which has been found to have good tensile strength and flexibility as well.^{20,21} The resiliency of the gasket ring affects the rate of recovery due to its viscoelastic properties. 3D-printed thermoplastic polyurethane is resilient in nature providing a cushion-like effect which can distribute forces more evenly by absorbing energy.^{13,16} In addition, the gasket ring also engages the undercut circumferentially on the abutment teeth, thereby increasing the retention and stability of the prosthesis by resisting lateral displacement.¹⁹ After the 2-year post-insertion review, there was no debonding of the ring from the denture. This proves that polyurethane had sufficient wear resistance with good longevity. Intraoral periapical radiograph of 13 during the 2-year review also revealed there was minimal bone loss, thus the gasket retained denture provided a cushioning effect without undue stress, unlike a clasp retained partial denture.

Conclusion

The treatment option of gasket retained Cu-sil denture is a viable option for prosthetic management of patients with a few remaining natural teeth. Fabrication of gasket rings with 3D printing technology ensures accurate fit and retention.

Conflict of Interest: None

References

1. Nidawani P, Vishnupriya BS, Galagali G, Naik S, Harsha RH. Preventive prosthodontics – an overview. *IP Ann Prosthodont Restor Dent.* 2022;8(2):69-75.

2. DeVan MM. The transition from natural to artificial teeth. *J Prosthet Dent.* 1961;11(4):677-88. [Google Scholar]
3. Emami E, de Souza RF, Kabawat M, Feine JS. The impact of edentulism on oral and general health. *Int J Dent.* 2013;2013:498305. [PubMed] [Google Scholar]
4. Bolender Z. *Prosthodontic treatment for edentulous patients: complete dentures and implant-supported prostheses.* 12th ed. St Louis, MO: Mosby; 2013. p. 6-23,76-160,190-208.
5. Crum RJ, Rooney Jr GE. Alveolar bone loss in overdentures: a 5-year study. *J Prosthet Dent.* 1978;40(6):610-3. [PubMed] [Google Scholar]
6. Van Waas MA, Jonkman RE, Kalk W, Van 't Hof MA, Plooij J, Van Os JH. Differences two years after tooth extraction in mandibular bone reduction in patients treated with immediate overdentures or with immediate complete dentures. *J Dent Res.* 1993;72(6):1001-4. [PubMed] [Google Scholar]
7. Cu-Sil [Internet]. Cu-Sil: a superior alternative!; [cited 2024 Jan 12]. Available from: <http://www.cu-sil.com/home.html>
8. Khandelwal M, Punia V. Saving one is better than none: technique for Cu-sil like denture – a case report. *Ann Ess Dent.* 2011;3(1):41-5. [Google Scholar]
9. Gagandeep K, Sangeetha G, Deepika S. Cusil denture: a novel conservative approach-a case report. *Unique J Med Dent Sci.* 2013;1(2):56-8.
10. Vinayagavel, Sabarigrinathan, Gunasekar, Hema. Cusil like denture - case report. *Int J Health Sci Res.* 2014;4(2):195-7. [Google Scholar]
11. Jain JK, Prabhu CR, Zahrane MA, Esawy MS, Ajagannavar SL, Pal KS. Cu-sil dentures - a novel approach to conserve few remaining teeth: case reports. *J Int Oral Health.* 2015;7(8):138-40. [PubMed] [Google Scholar]
12. Jain AR. Cu-sil denture for patients with few remaining teeth - a case report. *J Adv Pharm Educ Res.* 2017;7(3):333-5. [Google Scholar]
13. Zakaria WM. Fenestrated denture: a grace option to edentulous patient. *Int J Dent Sci Res.* 2017;5(2):31-4. [Google Scholar]
14. Arora A, Upadhyaya V, Malik D, Rohilla K. Cu-sil denture: conserving the remaining. *Int J Adv Res.* 2017;5(7):2086-91. [Google Scholar]
15. Gupta R, Luthra RP, Kumar A. Cusil like denture – a case report. *Int J Res Health Allied Sci.* 2019;5(3):100-3.
16. Goel D, Talukder D, Datta P, Paul G, Singh S. Cu-sil denture: an innovative approach to preserve the few remaining natural teeth: a case report. *Int J Sci Rep.* 2019;5(1):29-34. [Google Scholar]
17. Lavanya MK, Gnanam P, Muthukumar B. Cu-Sil dentures- an alternative treatment option for management of few remaining natural teeth. *Glob J Res Anal.* 2020;9(3):34-6.
18. Savitha K, Manoharan PS, Rajkumar E, Balaji J. FPD supported Cu-sil like denture - a simplified approach to preserve the teeth and bone. *Int J Health Sci Res.* 2021;11(6):130-4.
19. Dange SP, Dhage DT, Mahale KM, Khalikar SA. Cusil denture: a new esthetic approach to improve retention, stability and preserve remaining natural teeth and bone in macroglossia patient. *Int J Appl Dent Sci.* 2022;8(2):337-40. [Google Scholar]
20. Xu T, Shen W, Lin X, Xie YM. Mechanical properties of additively manufactured Thermoplastic Polyurethane (TPU) material affected by various processing parameters. *Polymers (Basel).* 2020;12(12):3010. [PubMed] [Google Scholar]
21. Pan R, Yang L, Zheng L, Hao L, Li Y. Microscopic morphology, thermodynamic and mechanical properties of thermoplastic polyurethane fabricated by selective laser sintering. *Mater Res Express.* 2020;7(5):055301. [Google Scholar]