

Research Article

A Case Series of Our Experiences with Rhinosporidiosis in a Tertiary Care Center

Priya K¹, Raghvi A²

¹Professor, ²Junior Resident, Department of ENT, Chettinad Academy of Research and Education, Chettinad Hospital and Research Institute, Kelambakkam, Tamil Nadu, India.

DOI: <https://doi.org/10.24321/2278.2044.202343>

I N F O

Corresponding Author:

Priya K, Department of ENT, Chettinad Academy of Research and Education, Chettinad Hospital and Research Institute, Kelambakkam, Tamil Nadu, India.

E-mail Id:

catchpriya.29@gmail.com

Orcid Id:

<https://orcid.org/0000-0003-4723-8414>

How to cite this article:

Priya K, Raghvi A. A Case Series of Our Experiences with Rhinosporidiosis in a Tertiary Care Center. Chettinad Health City Med J. 2023;12(3):3-8.

Date of Submission: 2023-01-13

Date of Acceptance: 2023-08-28

A B S T R A C T

Introduction: The cause of rhinosporidiosis, a chronic granulomatous lesion, is a fungus called *Rhinosporidium seeberi* that belongs to the phycomycete class of the Mesomycetozoa family. In most cases, it primarily affects the nose and nasopharynx. Clinically, it appears as a friable, irregular, reddish polypoidal mass with a history of recurrent epistaxis. Typically, a diagnosis is reached after the histological analysis of biopsy samples taken from polypoid lesions.

Methodology: The study was conducted at our institution's Department of Otorhinolaryngology on a total of 20 patients after receiving approval from the Institutional Human Ethics Committee.

Results: Out of these 20 patients, 12 had nasal rhinosporidiosis, 4 had lesions in the oropharynx, and 2 had lesions in the larynx and trachea. Two of these patients had malignant rhinosporidiosis. The mass was entirely excised via endoscopic sinus surgery, and the base was electro-cauterised to eliminate any potential of recurrence.

Conclusion: The benefit of this study was that a sizeable number of cases with a variety of presentations were examined. This study showed that early detection, prompt diagnosis, treatment, and a good follow-up are necessary for treating rhinosporidiosis.

Keywords: Lesion, Larynx, Spore, Epistaxis, Cautery

Introduction

The cause of rhinosporidiosis, a chronic granulomatous lesion, is a fungus called *Rhinosporidium seeberi* that belongs to the phycomycete class of the Mesomycetozoa family.^{1,2} In most cases, it primarily affects the nose and nasopharynx, although it can also affect the lacrimal sac, conjunctiva, palate, lips, uvula, epiglottis, maxillary antrum, larynx, bronchus, trachea, ear, skin, scalp, penis, vagina, and vulva.^{3,4} Although it often affects only the superficial epithelium, it can sometimes cause extensive visceral involvement.

Aim of the Study

To learn about the various symptoms, prognosis, and treatments of patients who presented with rhinosporidiosis at a tertiary care facility

Objectives of the Study

1. To identify the different clinical presentations in patients with rhinosporidiosis who presented to a tertiary care facility
2. To research the various management strategies and the results they produce for patients who are diagnosed with rhinosporidiosis in a tertiary care facility

Materials and Methodology

This study was carried out on 20 patients from February 2022 to March 2023 in our tertiary care centre in the Department of Otorhinolaryngology, after receiving approval from the Institutional Human Ethics Committee and consent from the participants and attendees. A case series-prospective type of research was conducted. Patients with additional signs of rhinosporidiosis and patients with symptoms from all age groups were included. Patients with other chronic granulomatous infections of the nose were excluded.

Patients who presented with rhinosporidiosis symptoms were assessed. A thorough case history was taken before the patients were evaluated through a clinical examination and radiological analysis.

History

The patient's name, age, primary complaint, personal habits, place of residence, bathing habits, occupation, history of discharge, nasal block, odour, colour, and characteristics of nasal discharge, history of headache, history of epistaxis, facial pain, heaviness, swelling, history of proptosis, visual disturbances, and history of diplopia were assessed. A thorough history of the patient's overall health, any prior injuries to the face or nose, previous exposure to contaminated water, etc., were evaluated.

Clinical Examination

An anterior rhinoscopy was performed as part of the clinical examination to check for polyps, nasal tumours, and sporangia. The nose and paranasal sinuses were also thoroughly examined. To look for any bleeding polyps, a thorough post-nasal examination as well as a diagnostic nasal endoscopy were performed. An examination of the oral cavity, oropharynx, ear, eye, and larynx was done to look for any extension of the rhinosporidiosis. Other systemic examinations also were done thoroughly. Routine tests including complete blood counts were conducted.

The following are the distinctive rhinosporidiosis characteristics that can aid in diagnosis: a history of exposure to contaminated water, a history of bleeding polyps sometimes protruding into the oropharynx, and subcutaneous nodules in case of disseminated form.

Radiological Evaluation

The "water's view" radiographs and computed tomography (CT) of the nose and paranasal sinus were two of the main radiological examinations done for rhinosporidiosis. The prevalence of polyps, severity of illness, bony expansion, any erosive changes were all documented. NCCT revealed soft tissue increasing density in the nasal cavities, nasopharynx, and oropharynx (Figure 1). The location and severity of the illness, as well as whether or not the adjacent bone, nasolacrimal duct, and

tracheobronchial tree are affected, are all clearly defined by contrast-enhanced CT. Before surgery, this imaging offers a helpful road map.⁵

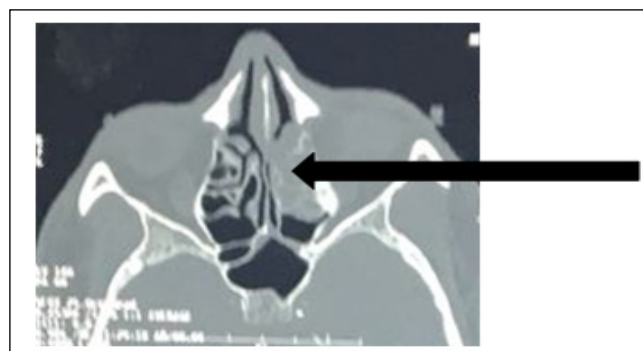


Figure 1. Axial Cut of CT Scan: Mass Seen in Left Nasal Cavity (Shown by an Arrow)

Clinical Presentation in Patients Presenting with Rhinosporidiosis in Our Tertiary Care Centre

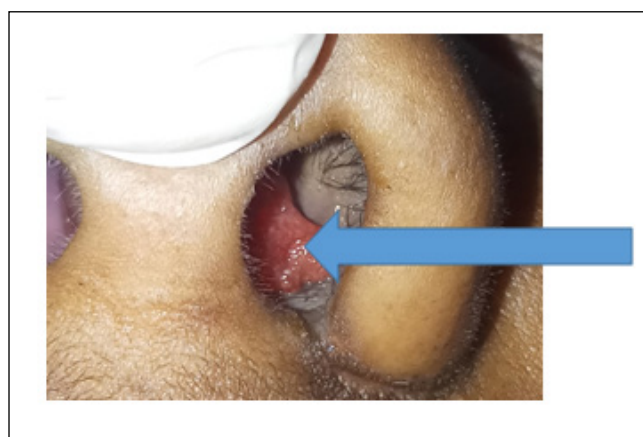


Figure 2. A Patient Presenting with Nasal Rhinosporidiosis (Arrow)

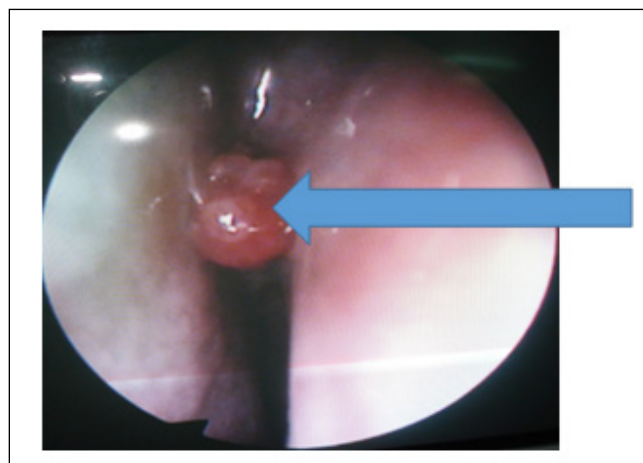


Figure 3. Left Nasal Cavity of a Patient with Rhinosporidiosis in a Diagnostic Nasal Endoscopic Picture (Arrow)

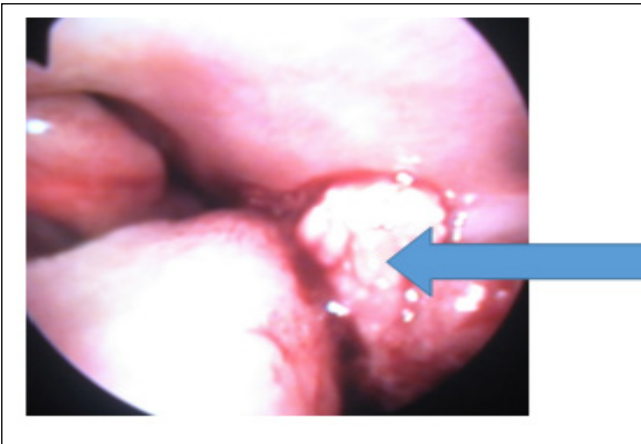


Figure 4.A Patient's Diagnostic Nasal Endoscopic Picture with Rhinosporidiosis in the Left Nasal Cavity showing the Characteristic Strawberry Pink Fleshy Mass (Arrow)

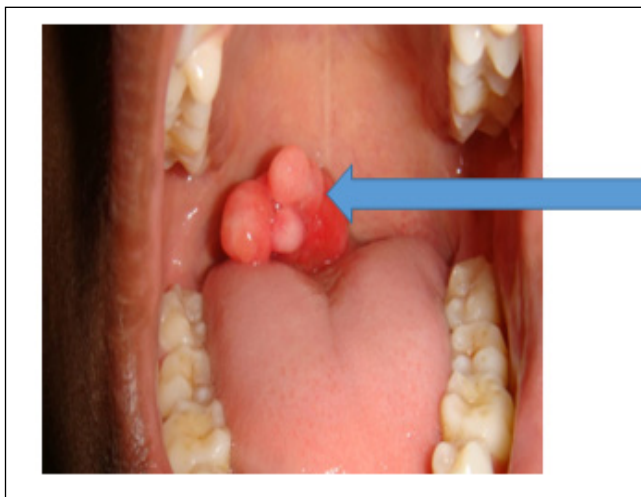


Figure 5.A Patient Presenting with Oropharyngeal Rhinosporidiosis (Arrow)

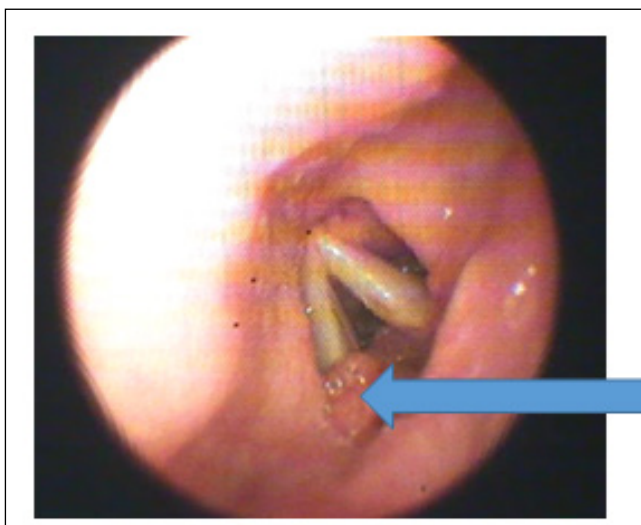


Figure 6.A Patient Presenting with Laryngeal Rhinosporidiosis (Arrow)

Patients from all age groups were included in this study and people with other granulomatous lesions of the nose were excluded from the study. There were 9 female and 11 male participants in our study. All these patients complained of a blocked nose, facial heaviness, and recurrent epistaxis. Eight patients had a history of exposure to contaminated water. Twelve among them had complaints of hyposmia. Out of these 20 patients, 12 had nasal rhinosporidiosis (Figures 2–4), 4 had lesions in the oropharynx (Figure 5), and 2 had lesions in the larynx and trachea (Figure 6) (Table 1). Two patients had malignant rhinosporidiosis a disseminated form of the disease which is a very rare entity.

Table 1. Various Types of Presentations Seen in Our Study

Presentation	Number of Patients
Nasal rhinosporidiosis	12
Oropharynx	4
Larynx and trachea	2
Malignant rhinosporidiosis	2
Total	20

Treatment

In our cases, the patients were evaluated and taken up for surgical excision of the lesions. The mass was resected completely by endoscopic sinus surgery and the base was electro-cauterised to prevent any chances of recurrence. The laryngeal, oropharyngeal and cutaneous lesions were also excised under strict haemostasis. The patients were on regular follow up to see if there was any recurrence of lesions. The excised specimens were sent for histopathology examination and were diagnosed as rhinosporidiosis.⁶ Figure 7 depicts the histopathology picture showing the sporangia with endospores.

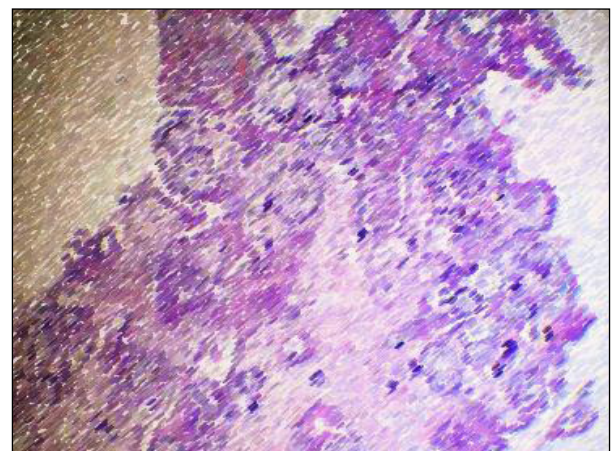


Figure 7.A Histopathology Picture showing Sporangia with Endospores (Arrow)

Discussion

Epidemiology

When Guillermo Seeber initially characterised the organism in the 1890s, he believed that the *Rhinosporidium seeberi* sporangium was a sporozoan.^{7,8} JR Seeber originally identified the phycomyce *Rhinosporidium seeberi* in 1900, and JH Ashworth thoroughly researched it in 1923. The organism's current classification as a member of the Mesomycetozoa family denotes its phylogenetic position at the evolutionary division between animals and fungi. Recently, Ahluwalia et al. postulated that the cause of rhinosporidiosis is the cyanobacterium *Microcystis aeruginosa*.⁹ All across the world, rhinosporidiosis has been documented, but it has been found to be more common in Asia. India and Sri Lanka account for the majority of these cases. It has been discovered that this organism, which is hyperendemic to Sri Lanka and Southern India, thrives best in hot tropical temperate regions. North and South America, Europe, Argentina, Brazil, Mexico, Venezuela, Columbia, Madagascar, Uganda, Iran, Ghana, Southeast Asia, and Russia are some of the regions where it is prevalent.¹⁰ Rhinosporidiosis is endemic in some areas of our nation, including the cities of Thanjavur, Madurai, and Kanyakumari in Tamil Nadu, as well as the Allepey, Kottayam, and Trivandrum districts of Kerala.¹¹ According to studies by Kutty et al., and Guru and Pradhan,^{12,13} most of the cases were seen in the age range of 21 to 30 years. Low socioeconomic position and bathing in ponds were found to be related to the occurrence of rhinosporidiosis (due to the lower levels of hygiene) in the studies conducted by Kutty et al., Guru and Pradhan, Arsecularatne et al., and Azad et al.¹²⁻¹⁵

Mode of Infection

Droplet infection, which is caused by close contact with contaminated people and animals, and sources like air, soil, and water, could be the method of transmission for this disease. When spores of *Rhinosporidium seeberi* are implanted over living tissues, they become active. The most frequent site affected is the nose, which supports the notion of droplet transmission. Auto-inoculation explains the reason for the involvement of nearby sites in the same individual.^{16,17}

Pathophysiology

Pedunculated or sessile growths that are spongy, friable, and polypoid are the hallmarks of rhinosporidiosis. The growths are granulomatous, myxoma-like, and haemorrhagic histologically, and they are frequently accompanied by the sporangium, a cyst with a thick wall that is excessively large and filled with many spores that may reach a size of 300 microns. Papillary processes of the epithelium can be observed in areas of proliferation. The sporangia

of *Rhinosporidium seeberi* are discovered in the fragile fibrous or fibromyxomatous tissue that lies underneath the epithelium. The sub-epithelial tissue has many fresh, newly formed capillaries and is highly vascular. Additionally noticeable are red blood cells, lymphocytes, plasma cells, and polymorph infiltration. Giant cells are rarely observed. Spores implanted in nasal mucosa can be found in the crypts created between the capillary processes. The sporangium releases these spores. Sporangia that have fully matured are found on the outside, whereas those that are still developing are found deep inside. One of the most notable characteristics of the tissues displaying *Rhinosporidium seeberi* invasion includes the paucity of inflammatory response.^{18,19} Figure 8 depicts the lifecycle of rhinosporidium showing its various stages. The fungus is detected using permanent stains like Giemsa, Gridley, and toluidine blue.

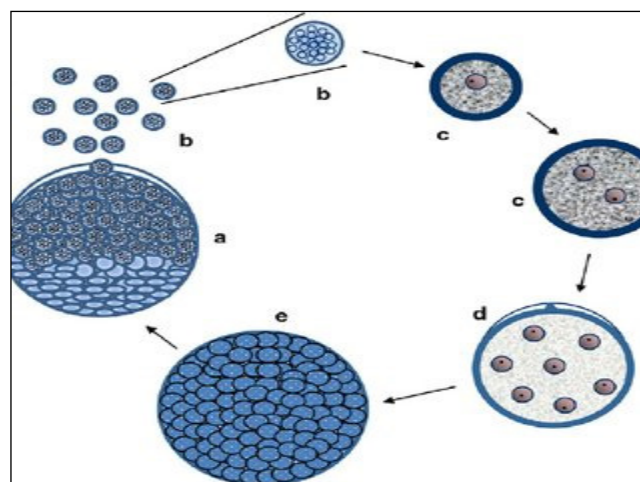


Figure 8. Lifecycle of *Rhinosporidium seeberi*

The sinonasal papilloma with cylindrical cells is a differential diagnosis. Microcysts of cylindrical cell papilloma are restricted to the epithelium and are absent from the submucosa, in contrast to rhinosporidiosis.

Clinical Presentation

Clinically, rhinosporidiosis manifests as a reddish polypoid mass that is irregular, friable, and has a history of recurrent epistaxis. Early stages have also reported viscid nasal discharge. Typically, a diagnosis is reached after the histological analysis of biopsy samples taken from polypoid lesions.

Anatomical obstruction to drainage may also impair ciliary activity and cause irritation and stagnation of secretion. The most frequent presenting complaints include nasal mass, nasal obstruction, and epistaxis. Depending on how widespread the infection is, there can be other manifestations including bone swelling, haemoptysis, and ocular and oral lesions. Although sporadic occurrences of nasopharyngeal involvement have been documented, rhinosporidiosis typically affects the nasal mucous

membrane. It appears as a soft, friable, and typically pedunculated pink or red papillomatous mass. It is a highly vascular swelling and bleeds on touch.^{20,21}

Rhinosporeidiosis can be diagnosed histologically in cases presenting with nasal polyps, and subcutaneous and osseous lesions. Both clinically and cytologically, the diagnosis of rhinosporeidiosis is due to specific clinical and cytological features. However, when seen in unexpected regions as recorded in rare cases, for instance, a lesion on the tibia or in the parotid duct,²² it is challenging to make a clinical and cytological diagnosis.

Management

The cornerstone of the treatment is the surgical removal of the tumour. To guarantee postoperative haemostasis and the complete eradication of this disease, surgical excision should be performed together with cauterisation of the tumour's base. The use of endoscopes is extremely beneficial in the surgical treatment of these patients. It assists in the early diagnosis of any recurrences and the assessment of the treatment's effectiveness. Rhinosporeidiosis is typically assumed to be unresponsive to antimycotic or antibiotic therapy. Systemic administration of amphotericin-B with dapsone is done in doses of 100 mg every day for 6 to 8 weeks. When there is either a recurrence or an insufficient surgical resection, amphotericin is often prescribed.²³⁻²⁵

Conclusion

This study comprised a number of cases that demonstrated a wide variety of diverse clinical manifestations, diagnosis, and treatment options for rhinosporeidiosis disease. The benefit of our study was that we examined numerous cases with a variety of appearances. Diligent case follow-ups were conducted, and none of our patients showed signs of recurrence. Our case series also included two cases with the malignant disseminated form of rhinosporeidiosis, which is a very rare form. The limitation of our study was the exclusion of paediatric cases. This study showed that early detection, prompt diagnosis, treatment, and a good follow-up are necessary. This disease can be controlled by proper hygiene, taking adequate precautions, and spreading the word of awareness to the public.

Source of Funding: None

Conflict of Interest: None

References

- Sharma KD, Junnarkar RV, Agarwal S. Rhinosporeidiosis. J Indian Med Assoc. 1962;38(12):640-2. [PubMed] [Google Scholar]
- Weir N, Goldingwood DG. Infective rhinitis and sinusitis. In: Scott-Brown WG, Kerr AG, editors. Scott-Brown's otolaryngology. 6th ed. Vol. 4. Butterworth-Heinemann; 1997. p. 39-40.
- Snidvongs ML, Supanakorn S, Supiyaphun P. Severe epistaxis from rhinosporeidiosis: a case report. J Med Assoc Thai. 1998 Jul;81(7):555-8. [PubMed] [Google Scholar]
- Cutchavaree A, Lekagul S, Sastarsadhit V, Sritulanondha S. Rhinosporeidiosis. J Med Assoc Thai. 1980;63(10):578-81. [PubMed] [Google Scholar]
- Kazi AZ, Kazi HZ, Channe RC, Kulkarni AS. Rhinosporeidiosis of maxillary sinus: a case report. J Indian Acad Oral Med Radiol. 2019;31(3):274. [Google Scholar]
- Van der Coer JM, Marres HA, Wielinga EW, Wong-Alcala LS. Rhinosporeidiosis in Europe. J Laryngol Otol. 1992;106(5):440-3. [PubMed] [Google Scholar]
- Venkatachalam VP, Anand N, Bhooshan O. Rhinosporeidiosis: its varied presentations. Indian J Otolaryngol Head Neck Surg. 2007 Jun;59(2):142-4. [PubMed] [Google Scholar]
- Fredricks DN, Jolley JA, Lepp PW, Kosek JC, Relman DA. *Rhinosporeidium seeberi*: a human pathogen from a novel group of aquatic protistan parasites. Emerg Infect Dis. 2000;6(3):273-82. [PubMed] [Google Scholar]
- Ahluwalia KB, Maheshwari N, Deka RC. Rhinosporeidiosis: a study that resolves etiologic controversies. Am J Rhinol. 1997;11(6):479-83. [PubMed] [Google Scholar]
- Salim T, Komu F. Varied presentations of cutaneous rhinosporeidiosis: a report of three cases. Indian J Dermatol. 2016 Mar;61(2):209. [PubMed] [Google Scholar]
- Thankamani V, Lipin Dev MS. *Rhinosporeidium seeberi* proven as a fungus for the first time after a century since its discovery. Res Biotechnol. 2012;3(1):41-6. [Google Scholar]
- Kutty MK, Sreedharan T, Mathew KT. Some observations on rhinosporeidiosis. Am J Med Sci. 1963;246:695-701. [PubMed] [Google Scholar]
- Guru RK, Pradhan DK. Rhinosporeidiosis with special reference to extra nasal presentation. J Evol Med Dent Sci. 2014;22(3):6189-99. [Google Scholar]
- Arseculeratne SN, Sumathipala S, Eriyagama NB. Patterns of rhinosporeidiosis in Sri Lanka: comparison with international data. Southeast Asian J Trop Med Public Health. 2010;41(1):175-91. [PubMed] [Google Scholar]
- Azad NS, Ahmad Z, Kayani N. Rhinosporeidiosis presenting as an urethral polyp. J Coll Physicians Surg Pak. 2008;18(5):314-5. [PubMed] [Google Scholar]
- Jain MR, Sahai R. Rhinosporeidiosis of lacrimal sac. Indian J Ophthalmol. 1974;22(3):29-31. [PubMed] [Google Scholar]
- Krishnamoorthy S, Sreedharan VP, Koshy P, Kumar S, Anilakumari CK. Culture of *Rhinosporeidium seeberi*: preliminary report. J Laryngol Otol. 1989;103(2):178-80. [PubMed] [Google Scholar]

18. Karthikeyan P, Vijayasundaram S, Pulimoottil DT. A retrospective epidemiological study of rhinosporidiosis in a rural tertiary care centre in Pondicherry. *J Clin Diagn Res.* 2016 May;10(5):MC04. [PubMed] [Google Scholar]
19. Arseculeratne SN. Rhinosporidiosis: what is the cause? *Curr Opin Infect Dis.* 2005 Apr;18(2):113-8. [PubMed] [Google Scholar]
20. Gori S, Scasso A. Cytologic and differential diagnosis of rhinosporidiosis. *Acta Cytol.* 1994;38(3):361-6. [PubMed] [Google Scholar]
21. Ratnakar C, Madhavan M, Sankaran V, Veliath AJ, Majumdar NK, Rao VA. Rhinosporidiosis in Pondicherry. *J Trop Med Hyg.* 1992;95(4):280-3. [PubMed] [Google Scholar]
22. Kini U, Amirtham U, Shetty SC, Balasubramanya AM. Rhinosporidiosis of the parotid duct cyst: cytomorphological diagnosis of an unusual extranasal presentation. *Diagn Cytopathol.* 2001 Oct;25(4):244-7. [PubMed] [Google Scholar]
23. Ali A, Flieder D, Guiter G, Hoda SA. Rhinosporidiosis: an unusual affliction. *Arch Pathol Lab Med.* 2001;125(10):1392-3. [PubMed] [Google Scholar]
24. Nair KK. Clinical trial of diaminodiphenylsulphone (DDS) in nasal and nasopharyngeal rhinosporidiosis. *Laryngoscope.* 1979;89(2 Pt 1):291-5. [PubMed] [Google Scholar]
25. Mears T, Amerasinghe C. Rhinosporidiosis. *J Laryngol Otol.* 1992;106(5):468. [PubMed] [Google Scholar]