

Research Article

# A Comparative Analysis of Diagnostic Imaging in Acute Ischaemic Stroke

Dupinder Kaur<sup>1</sup>, RP Bansal<sup>2</sup>, Ashok Uppal<sup>3</sup>

<sup>1</sup>Research Scholar, NIMS University, Jaipur, Rajasthan, India.

<sup>2</sup>Professor & Head, Department of Radio-diagnosis, National Institute of Medical Sciences & Research, NIMS University, Jaipur, Rajasthan, India.

<sup>3</sup>Associate Professor, Guru Nanak Dev University, Amritsar, Punjab, India.

DOI: <https://doi.org/10.24321/2278.2044.202320>

## I N F O

### Corresponding Author:

Dupinder Kaur, NIMS University, Jaipur, Rajasthan, India.

### E-mail Id:

[dupinder\\_kaur@outlook.com](mailto:dupinder_kaur@outlook.com)

### Orcid Id:

<https://orcid.org/0009-0006-1261-5629>

### How to cite this article:

Kaur D, Bansal RP, Uppal A. A Comparative Analysis of Diagnostic Imaging in Acute Ischaemic Stroke. Chettinad Health City Med J. 2023;12(2):3-8.

Date of Submission: 2022-12-07

Date of Acceptance: 2023-04-17

## A B S T R A C T

**Introduction:** Acute ischaemic stroke (AIS) is responsible for almost 90% of all strokes. Large vessel occlusion is mainly responsible for AIS. Earlier treatment of AIS is associated with improved outcomes. Multimodal imaging methods such as MRI and CT provide information that can help in diagnosing it. These methods are helpful in the prognosis of AIS and in the selection of patients who can be subjected to thrombolytic therapy.

**Objectives of the Study:** The present comparative study has been conducted to understand whether MRI images are better for the diagnosis of AIS than CT, to assess the efficacy of tPA in the recovery of patients, and to explore the role of advanced imaging in acute stroke.

**Methods:** The present study was conducted with 40 patients, aged 18 years and above who presented to the Emergency Department of Uppal Neuro Hospital, Amritsar, Punjab with a history of acute ischaemic stroke or hyperacute stroke between September 2017 and March 2018. All patients were examined using 32 slices CT and 1.5T MRI scanner. Among all cases, 17 patients had suffered a hyperacute stroke and 23 had suffered an acute ischaemic stroke.

**Results:** It was observed that AIS-associated changes are detectable sooner with MRI as compared to CT. MRI has a higher interobserver and intraobserver reliability as seen with diffusion-weighted imaging MRI as compared to CT in the diagnosis of AIS. Patients who were treated with tPA were found to recover quickly as compared to those who were not treated with tPA.

**Conclusion:** Sophisticated techniques such as perfusion imaging and non-invasive vascular imaging are becoming more effective tools for guiding prospective endovascular treatment or extending therapy windows in the case of patients with acute ischaemic stroke.

**Keywords:** MRI, AIS, Acute Ischaemic Stroke, Thrombolysis, Computed Tomography, CT, Ischaemic Stroke, Magnetic Resonance Imaging

## Introduction

Acute ischaemic stroke (AIS) is the most common type of stroke. It has been observed to be the main causative agent in 90% of all reported cases. Clot formation in the brain artery is the primary cause of AIS. Clots are classified as either thrombotic or embolic depending on their origin in the human body. A thrombotic stroke is more common than an embolic stroke and manifests in the brain when the artery in it develops a clot. Unlike thrombotic strokes, embolic strokes are characterised by the migration of clots generated elsewhere in the body through the bloodstream to the brain wherein they get stuck in the narrow lumen of blood vessels resulting in a blockage. 50% of AIS observed in patients is due to occlusion of the large vessel (LVO), which is the most severe type of clot and often results in debilitating strokes that cut off blood flow to a significant portion of the brain.<sup>1</sup>

Earlier treatment of AIS is associated with improved outcomes in patients. Early detection helps in the dissolution of the clots by intravenous injection of recombinant tissue plasminogen activator.<sup>2</sup> Another thrombolytic agent used is alteplase which decreases the risk of long-term disability after AIS. However, it is associated with a risk of bleeding in the brain with around 6% of the injected patients showing this side effect.<sup>3</sup> Another disadvantage of using alteplase is the fact that depending on the nature of the arteries blocked in the brain, blood flow is restored only in 10%-50% of cases.<sup>4</sup>

Stroke is one of the major causes of long-term disability in developed nations and is associated with significant mortality. A large number of advanced diagnostic and treatment options have been discovered in the last decade which have led to minimisation of the impact of AIS. The key step in stroke care is associated with the earliest identification of stroke and transportation of patients to medical centres. The use of emergency medical service protocol for identifying patients and intravenous thrombolysis are the major measures that need to be addressed during the stroke.<sup>5</sup> According to the patient's eligibility, requirements, and treatment duration, the use of modern imaging techniques with an automatic interpretation function might benefit patients who are in danger of brain injury without having bigger infarcts. When doing endovascular thrombectomy on such patients over a long period of time following the emergence of initial symptoms, the utilisation of these cutting-edge technologies is incredibly helpful. Dual antiplatelet medication has been strongly advised for usage throughout the high-risk period following a stroke for the prevention of recurrent strokes, according to an analysis of current protocols.<sup>6</sup>

When performed within 24 hours after stroke symptoms, AIS caused by blockage of big blood arteries in the brain

may be addressed by the mechanical removal of clots. A catheter is used for mechanical removal, which entails directing the catheter to the damaged blood artery in the brain while being continuously monitored via X-ray imaging. The catheter is inserted into the arm or leg.<sup>7</sup> The clot is then eliminated using wire mesh tape or suction. Alteplase has worse results than mechanical thrombectomy, but such complex techniques are not accessible in every institution. Individuals who respond poorly to alteplase may be moved to a facility that does mechanical thrombectomy so that they might benefit from this technique.<sup>8</sup>

The acute phase of ischaemic stroke can be detected by Multimodal magnetic resonance imaging (MRI). Early detection is very useful in determining the treatment strategy. Early stroke diagnosis may assist in distinguishing it from stroke imitators, allowing for better therapy depending on the symptoms.<sup>9</sup> Several MRI scans taken at various times aid in identifying the stroke processes and eventually play a crucial role in therapy. The varied MRI lesion profiles help in determining the advantages and risks of thrombolysis. The best information on the age of ischaemic lesions and the amount of tissue that can be saved comes from MRI.<sup>10</sup> The thrombolysis trials conducted on patients in previous research using the MRI image-based analysis, however, were not particularly successful. Although MRI may give a general picture of how a stroke is progressing, it is highly advised frequently to understand the mechanics underlying stroke creation and weigh the risks and benefits depending on many clinical factors. The optimum stroke therapy at any particular moment would be determined by a thorough study based on images and other factors as well as an appropriate clinical interpretation of the MRI images.<sup>11</sup>

Clinical presentation is often the main method for the diagnosis of stroke.<sup>12</sup> Around 19%-30% of suspected stroke cases are due to stroke mimics that originate due to distinct underlying aetiological causes. Any specific focal neurological problem presented to physicians needs to have a broad diagnosis on different fronts. The development of advanced techniques in MRI has helped in the identification of ischaemic lesions with high accuracy. The use of diffusion-weighted MRI images has contributed significantly to the field of diagnosis.<sup>13</sup> In a diffusion-weighted MRI (DWI), the lesions associated with stroke appear as hyperintense areas and hypointense areas on apparent diffusion coefficient (ADC) maps. The changes are detected within 3 minutes of stroke onset making it very sensitive. MRI is also effective in the detection of lesions in the brain stem at an acute stage, which usually go undetected in CT scans. It, however, can miss out mild lesions in the brain stem associated with ataxic hemiparesis or internuclear ophthalmoplegia. High-intensity lesions seen on DWI could also be due to underlying neurological conditions and thus performing follow-up images along with the clinical presentation would

be of immense help in understanding the aetiology of the disease.<sup>6</sup>

Studies have been done to understand and evaluate the pathological mechanism of ischaemic lesions based on images from DWI. On DWI, the atherosclerosis of a large artery appears as multiple lesions in the unilateral anterior circulation or as scattered lesions in one of the regions of the artery.<sup>14</sup> The pattern of atherosclerotic regions on DWI is distinct from perforating or border zone infarcts of the blood vessels. MRI is highly sensitive in detecting lacunar infarcts which are small and go undetected in CT. Fluid-attenuated inversion recovery (FLAIR) image helps in demonstrating the subacute or chronic ischaemic lesions which are helpful in classifying the stroke further.<sup>15</sup> Imaging based on MRI is helpful in the diagnosis of ischaemic stroke, identification of patients suitable for thrombolytic therapy, and also in the prediction of the progress of stroke. Instead of depending on a few parameters, MRI images need to be combined and various mismatch parameters need to be utilised in establishing MRI-based thrombolysis.<sup>16</sup>

Clinical parameters such as neurological deficit scores (NIHSS scores) that are used for assessing functional disability often miss the lesion due to multiple factors including patient age and the type of treatment undergone by the patient. On the contrary, imaging methods have the advantage that they measure the treatment directly by monitoring the initial infarction core, penumbra, and final infarction volume.<sup>17</sup>

There are three major outcome measures indicated by MRI which include PWI lesion volume change, DWI lesion volume change, and recanalisation of the occluded vessel on MRA. However, there is universal consensus on how to determine infarct growth even by MRI. It is usually measured by evaluating the change in lesion volume between baseline and follow-up MRI. In one of the trial studies termed EPITHET (Echoplanar Imaging Thrombolytic Evaluation Trial), different measures for infarct growth were suggested including geometric mean and difference in cube root volumes. However, not all of these are easy to use and the parameters might alter from study to study making it difficult to compare the results.<sup>18</sup>

## Aims and Objectives

The objectives of the study are:

- To assess if MRI images are more effective than CT images for the diagnosis of acute ischaemic stroke
- To effectively analyse and compare the patients treated with tPA and those who were not treated with tPA
- To explore the role of advanced imaging in acute stroke

## Materials and Methods

The present study was conducted with 40 patients, aged 18 years and above who presented to the Emergency

Department of Uppal Neuro Hospital, Amritsar, Punjab with a history of acute ischaemic stroke or hyperacute stroke between September 2017 and March 2018. The study was carried out in the Department of Radiology, Uppal Neuro Hospital Amritsar. In order to fulfil the aims of the study, a comparative research design was adopted.

All patients were examined using 32 slices CT and 1.5T MRI scanner. Among all cases, 17 patients had suffered a hyperacute stroke and 23 patients had suffered an acute ischaemic stroke. Only patients with positive findings were included. A complete history of all stroke patients was taken. 17 hyperacute patients were treated with tPA and 23 patients were not treated with tPA.

## Inclusion Criteria

- Age 18 years and above
- No evidence of intracranial haemorrhage
- Time of onset (when the patient was last seen as normal) less than 6 hours before treatment

## Exclusion Criteria

- Arterial puncture at a non-compressible site within the last 7 days
- Any major surgery or major trauma
- Patient or family unwilling to participate

The statistics were analysed with the aid of Statistical Package for the Social Sciences (SPSS) model 15.0.

## Ethical Considerations

Ethical consideration is the most crucial and important section of any research.<sup>19</sup> It becomes very important while dealing with human subjects as participants.<sup>20</sup> Informed consent was taken from all patients who were enrolled in the study. The analysed data were kept highly confidential. The study was approved by the Institutional Ethics Committee.

## Results

To assess if MRI Images are More Effective than CT Images for the Diagnosis of Acute Ischaemic Stroke

As can be seen in Figure 1, MRI images are more effective than CT images and have significantly higher sensitivity as well as specificity in the diagnosis of acute ischaemic infarction in the first few hours after onset. MRI can detect brain blockage within an hour of the onset of stroke symptoms while CT scan takes several hours to reveal blockage in the blood flow.

To Effectively Analyse and Compare the Patients Treated with tPA and Those who were Not Treated with tPA.

Figure 2 shows the images of a patient treated with tPA who recovered completely within 2 months. As is seen in the figure, a non-contrast CT scan does not show ischaemic changes but on MRI images (T2, DWI, ADC, and PWI), we can clearly see these changes.

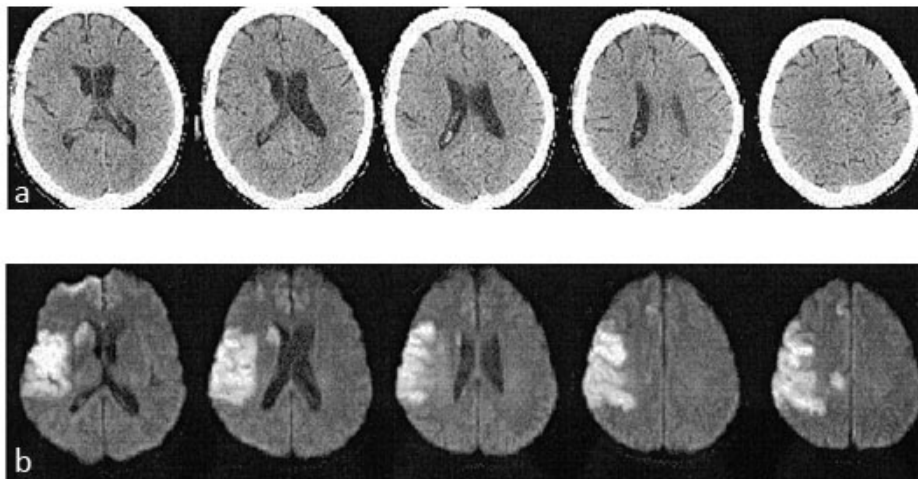


Figure 1. Comparison of CT and MRI Images (a).CT Image (b).MRI DWI Image

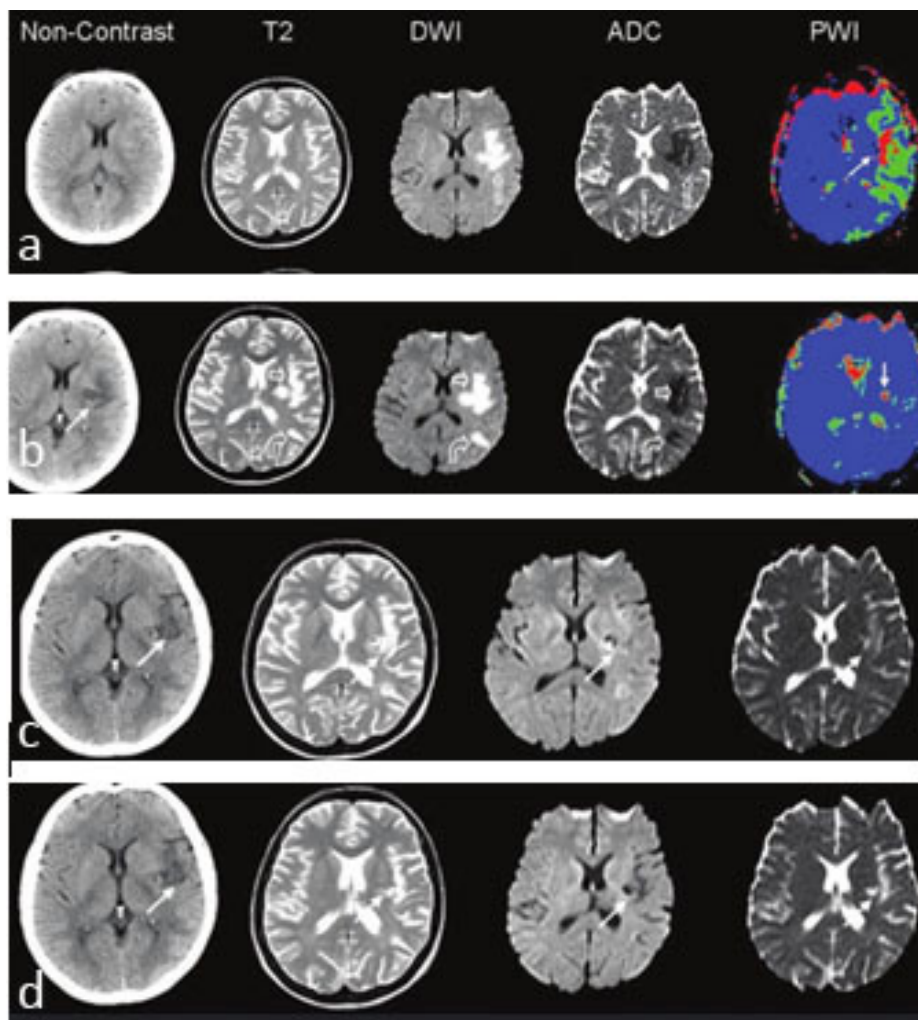
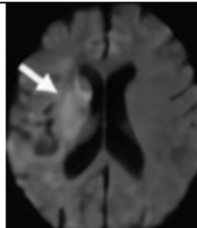
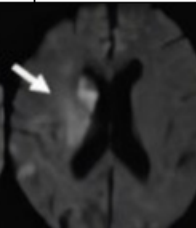
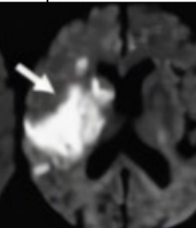
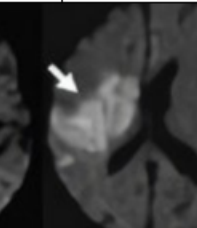
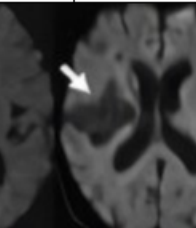
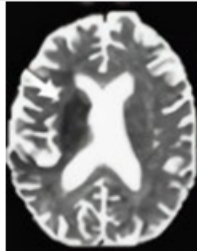
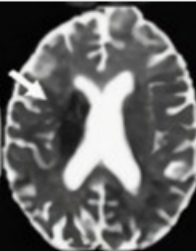
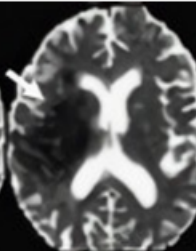
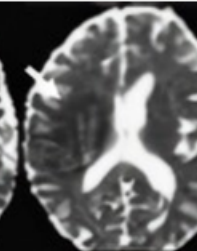
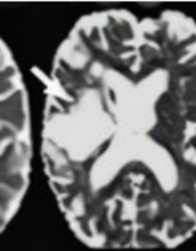


Figure 2. Images of a Patient Treated with tPA (a).First Day (b).Second Day (c).After 2 Weeks (d).After 2 Months

Table 1 shows the images of a patient who was not treated with tPA. The recovery of this patient was slow (after 3 months) as compared to the one who was given tPA (within 2 months).

Table I. Images of a Patient who was Not Given tPA

Imaging	6 hours	9 hours	2 days	5 days	3 months
DWI					
ADC					

### To Explore the Role of Advanced Imaging in Acute Stroke Diagnosis

The use of advanced imaging technology (CT and MRI) has helped diagnose and treat acute strokes. An MRI can get a better view of the brain, detecting stroke-causing blockages or bleeding, while a CT scan can detect changes in the blood vessels. The extent and severity of a stroke can also be determined with advanced imaging techniques like diffusion-weighted imaging (DWI) and perfusion-weighted imaging (PWI). Improvements in diagnostic accuracy and treatment options have led to better outcomes for patients. As a result, advanced imaging technology has played a huge role in stroke diagnosis and treatment.

### Discussion

In the initial few hours, MRI scans are substantially more sensitive and specific than CT imaging in the diagnosis of acute ischaemic infarction. Psychogios and Tsvigoulis have stated that multimodal MRI helps to diagnose more therapeutic responses and interventions in case of stroke.<sup>21</sup> The early signs of acute ischaemic stroke are hypoattenuation, parenchymal swelling,<sup>22</sup> and infarction in brain territory, which can be easily accessed through MRI. The DWI MRI can significantly identify minor strokes which may not be detected in the case of a CT scan. According to the National Institute of Health, MRI images are better for the detection of AIS and any other stroke, which is similar to the results of our study.<sup>23</sup>

Provost et al. have stated that the duration of MRI is slightly longer than that of a CT scan but it can be done within a reasonable timeframe, while not delaying the treatment or adversely impacting functional outcomes.<sup>13</sup>

### Conclusion

This study shows the efficacy of tPA in faster recovery of patients. It can also be concluded that MRI can be a more useful and accurate strategy to analyse strokes as compared to CT. Sophisticated techniques such as perfusion imaging and non-invasive vascular imaging are becoming more effective tools for guiding prospective endovascular treatment or extending therapy windows.

**Source of Funding:** Nil

**Conflict of Interest:** Nil

### References

1. Sundaram VK, Goldstein J, Wheelwright D, Aggarwal A, Pawha PS, Doshi A, Fifi JT, Leacy RD, Mocco J, Puig J, Nael K. Automated ASPECTS in acute ischemic stroke: a comparative analysis with CT perfusion. *AJNR Am J Neuroradiol.* 2019;40(12):2033. [PubMed] [Google Scholar]
2. Zhang R, Zhao L, Lou W, Abrigo JM, Mok VC, Chu WC, Wang D, Shi L. Automatic segmentation of acute ischemic stroke from DWI using 3-D fully convolutional DenseNets. *IEEE Trans Med Imaging.* 2018;37(9):2149-60. [PubMed] [Google Scholar]
3. Jahan R, Saver JL, Schwamm LH, Fonarow GC, Liang L, Matsouaka RA, Xian Y, Holmes DN, Peterson ED, Yavagal D, Smith EE. Association between time to treatment with endovascular reperfusion therapy and outcomes in patients with acute ischemic stroke treated in clinical practice. *JAMA.* 2019;322(3):252-63. [PubMed] [Google Scholar]
4. Tsvigoulis G, Geisler F, Katsanos AH, Körv J, Kunz A, Mikulik R, Rozanski M, Wendt M, Audebert HJ. Ultraearly

- intravenous thrombolysis for acute ischemic stroke in mobile stroke unit and hospital settings: a comparative analysis. *Stroke*. 2018;49(8):1996-9. [PubMed] [Google Scholar]
5. Demeestere J, Wouters A, Christensen S, Lemmens R, Lansberg MG. Review of perfusion imaging in acute ischemic stroke: from time to tissue. *Stroke*. 2020;51(3):1017-24. [PubMed] [Google Scholar]
  6. Kim JT, Cho BH, Choi KH, Park MS, Kim BJ, Park JM, Kang K, Lee SJ, Kim JG, Cha JK, Kim DH, Nah HW, Park TH, Park SS, Lee KB, Lee J, Hong KS, Cho YJ, Park HK, Lee BC, Yu KH, Oh MS, Kim DE, Ryu WS, Choi JC, Kwon JH, Kim WJ, Shin DI, Yeo MJ, Sohn SI, Hong JH, Lee JS, Lee J, Bae HJ, Cho KH. Magnetic resonance imaging versus computed tomography angiography based selection for endovascular therapy in patients with acute ischemic stroke. *Stroke*. 2019;50(2):365-72. [PubMed] [Google Scholar]
  7. Zerna C, Thomalla G, Campbell BC, Rha JH, Hill MD. Current practice and future directions in the diagnosis and acute treatment of ischaemic stroke. *Lancet*. 2018;392(10154):1247-56. [PubMed] [Google Scholar]
  8. Rajashekar D, Hill MD, Demchuk AM, Goyal M, Fiehler J, Forkert ND. Prediction of clinical outcomes in acute ischaemic stroke patients: a comparative study. *Front Neurol*. 2021;12:678. [PubMed] [Google Scholar]
  9. Mokin M, Ansari SA, McTaggart RA, Bulsara KR, Goyal M, Chen M, Fraser JF; Society of NeuroInterventional Surgery. Indications for thrombectomy in acute ischemic stroke from emergent large vessel occlusion (ELVO): report of the SNIS Standards and Guidelines Committee. *J Neurointerv Surg*. 2019;11(3):215-20. [PubMed] [Google Scholar]
  10. Tao J, Cai Y, Dai Y, Xie Y, Liu H, Zang X. Value of 4D CT angiography combined with whole brain CT perfusion imaging feature analysis under deep learning in imaging examination of acute ischemic stroke. *Comput Intell Neurosci*. 2022;2022:2286413. [PubMed] [Google Scholar]
  11. Kwon Y, Won JH, Kim BJ, Paik MC. Uncertainty quantification using Bayesian neural networks in classification: application to ischemic stroke lesion segmentation. *Medical Imaging with Deep Learning*. 2018. [Google Scholar]
  12. Sharma R, Silverman S, Patel S, Schwamm LH, Sanborn DY. Frequency, predictors and cardiovascular outcomes associated with transthoracic echocardiographic findings during acute ischaemic stroke hospitalisation. *Stroke Vasc Neurol*. 2022;7(6):482-92. [PubMed] [Google Scholar]
  13. Provost C, Soudant M, Legrand L, Ben Hassen WB, Xie Y, Soize S, Borcier R, Benzakoun J, Edjlali M, Boulousi G, Raoult H, Guillemin F, Naggara O, Bracard S, Oppenheim C. Magnetic resonance imaging or computed tomography before treatment in acute ischemic stroke: effect on workflow and functional outcome. *Stroke*. 2019;50(3):659-64. [Google Scholar]
  14. Jeena RS, Kumar S. A comparative analysis of MRI and CT brain images for stroke diagnosis. 2013 Annual International Conference on Emerging Research Areas and 2013 International Conference on Microelectronics, Communications and Renewable Energy. 2013. p. 1-5. [Google Scholar]
  15. Kim BJ, Kang HG, Kim HJ, Ahn SH, Kim NY, Warach S, Kang DW. Magnetic resonance imaging in acute ischemic stroke treatment. *J Stroke*. 2014;16(3):131. [PubMed] [Google Scholar]
  16. Macha K, Hoelter P, Siedler G, Knott M, Schwab S, Doerfler A, Kallmunzer B, Engelhorn T. Multimodal CT or MRI for IV thrombolysis in ischemic stroke with unknown time of onset. *Neurology*. 2020;95(22):e2954-64. [PubMed] [Google Scholar]
  17. Wang Y, Jing J, Meng X, Pan Y, Wang Y, Zhao X, Lin J, Li W, Jiang Y, Li Z, Zhang X, Yang X, Ji R, Wang C, Wang Z, Han X, Wu S, Jia Z, Chen Y, Li H. The third China National Stroke Registry (CNSR-III) for patients with acute ischaemic stroke or transient ischaemic attack: design, rationale and baseline patient characteristics. *Stroke Vasc Neurol*. 2019;4(3):158-64. [PubMed] [Google Scholar]
  17. Rudkin S, Cerejo R, Tayal A, Goldberg MF. Imaging of acute ischemic stroke. *Emerg Radiol*. 2018;25(6):659-72. [Google Scholar]
  18. Fotrousi F, Seyff N, Borstler J. Ethical considerations in research on user feedback. 2017 IEEE 25th International Requirements Engineering Conference Workshops (REW). 2017. p. 194-8. [Google Scholar]
  19. Arifin SR. Ethical considerations in qualitative study. *Int J Care Scholars*. 2018;1(2):30-3. [Google Scholar]
  20. Psychogios K, Tsivgoulis G. Intravenous thrombolysis for acute ischemic stroke: why not? *Curr Opin Neurol*. 2022;35(1):10-7. [PubMed] [Google Scholar]
  21. Grotta JC. Intravenous thrombolysis for acute ischemic stroke. *Continuum (Minneap Minn)*. 2023;29(2):425-42. [PubMed] [Google Scholar]
  22. Lansberg MG, Albers GW, Beaulieu C, Marks MP. Comparison of diffusion-weighted MRI and CT in acute stroke. *Neurology*. 2000;54(8):1557-61. [PubMed] [Google Scholar]