

Case Study

A Rare Complication of Neglected Workplace Trauma Leading to Fistula Formation

*Dhivya Ravikumar*¹, *Kishore Babu*²

¹Postgraduate, ²Professor, Department of General Surgery, Chettinad Hospital & Research Institute, OMR, Kelambakkam, Chennai, Tamil Nadu, India.

DOI: <https://doi.org/10.24321/2278.2044.202318>

I N F O

Corresponding Author:

Kishore Babu, Department of General Surgery, Chettinad Hospital & Research Institute, OMR, Kelambakkam, Chennai, Tamil Nadu, India.

E-mail Id:

kishorearjun86@gmail.com

Orcid Id:

<https://orcid.org/0000-0003-1984-1419>

How to cite this article:

Ravikumar D, Babu K. A Rare Complication of Neglected Workplace Trauma Leading to Fistula Formation. Chettinad Health City Med J. 2023;12(1):107-110.

Date of Submission: 2022-08-30

Date of Acceptance: 2022-12-30

A B S T R A C T

A long-term retained foreign body is rare and could lead to abnormal fistula formation. We present the case of a 25-year-old male with purulent discharge from the dorsal aspect of the left foot caused by a retained foreign body. The retained foreign body, a piece of rubber slipper retained over the past one year due to workplace injury to his left foot resulted in the formation of a fistula, a rare complication. The diagnosis was confirmed intraoperatively. We performed an emergency exploration of the left foot, the adhesions around the fistula were dissected, and we excised the fistula along with the foreign body. No severe complications occurred after surgery. We report this case to highlight that neglected foreign bodies can lead to various complications and healthcare professionals should be able to diagnose them with adequate imaging modalities.

Keywords: Foreign Body, Fistula, Cellulitis

Introduction

Neglected foreign body leading to fistula formation is a rare entity. A persistent fistula is caused by a foreign body or necrotic tissue underneath. However, it is very difficult to detect foreign bodies embedded inside soft tissue.

A long-standing foreign body leads to chronic infection and can lead to serious complications like cellulitis, fistula formation, and abscess formation. Hence it should be removed in time. However, a surgical approach is needed otherwise it can lead to slow healing, reduced quality of life and chronic infection.

Case Report

A case of sinus of the left foot with a neglected foreign body is presented here. A 25-year-old male patient came with complaints of pain and purulent discharge from the dorsal aspect of the left foot for the last 6 months. He

reported a history of trauma to his left foot one year back at his workplace following which he developed discharge from the plantar aspect of the left foot. One year back, he was conservatively treated with antibiotics and analgesics.

On examination of the left foot, multiple discharging sinuses were observed in the dorsal and plantar aspects of the left foot. Severe tenderness was present with no swelling (Figures 1 and 2).

MRI left foot showed T2/ STIR hyperintense collection of size 2.1 x 1.2 cm noted between the 3rd and 4th metatarsal bone along the plantar aspect (Figure 3). External skin surface communicating hyperintense single tract noted extending antero superiorly up to the 4th and 5th interphalangeal joint on the dorsal aspect of the foot. A tract ran for a length of about 35 mm. Another external skin surface communicating hyperintense single tract running for a length of 10 mm was noted extending inferiorly from

the collection of the plantar aspect. A blind tract was seen extending medially from the collection up to the base of the second metatarsal bone running for a length of 7 mm.

After obtaining informed and written consent from the patient, he was taken up for exploration and was given spinal anaesthesia. A fistula probe was inserted through the dorsal aspect of the left foot and the other end was taken out from the plantar aspect of the left foot.

Intraoperative Findings

Plantar Aspect

While trying to probe through the plantar aspect, a small foreign object of size 1 x 1 cm was observed (Figure 4). It was rubbery in consistency and was embedded between the first and second metatarsal bones (Figure 5). The entire fistula tract was removed in toto with the foreign body and was sent for HPE. Postoperatively, the patient had an uneventful recovery and was discharged on post-op day 5.

Result

A microscopic section showed a fistulous tract lined by granulation tissue composed of proliferating capillaries and fibroblasts surrounded by acute on chronic inflammatory infiltrates composed of lymphocytes and multinucleated foreign body giant cells with granuloma and histocytes. Overlying skin showed hyperkeratosis and acanthosis. A fistulous tract with foreign body granuloma was seen.

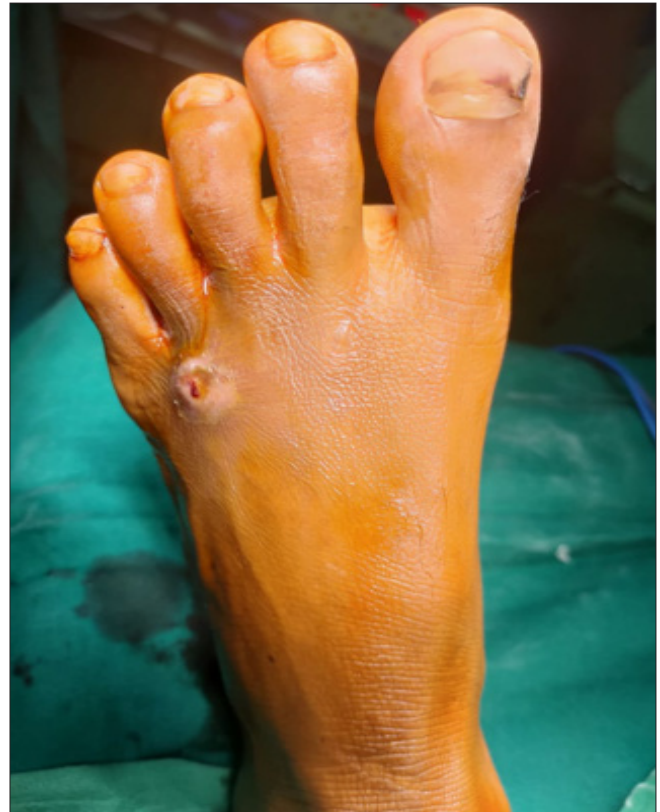

Figure 2. Plantar Aspect of the Left Foot

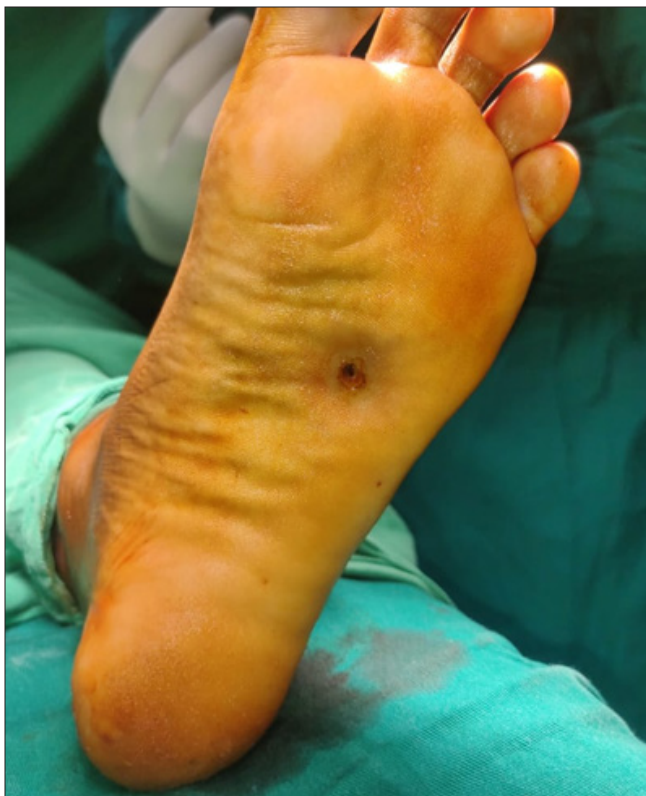

Figure 1. Dorsal Aspect of the Left Foot

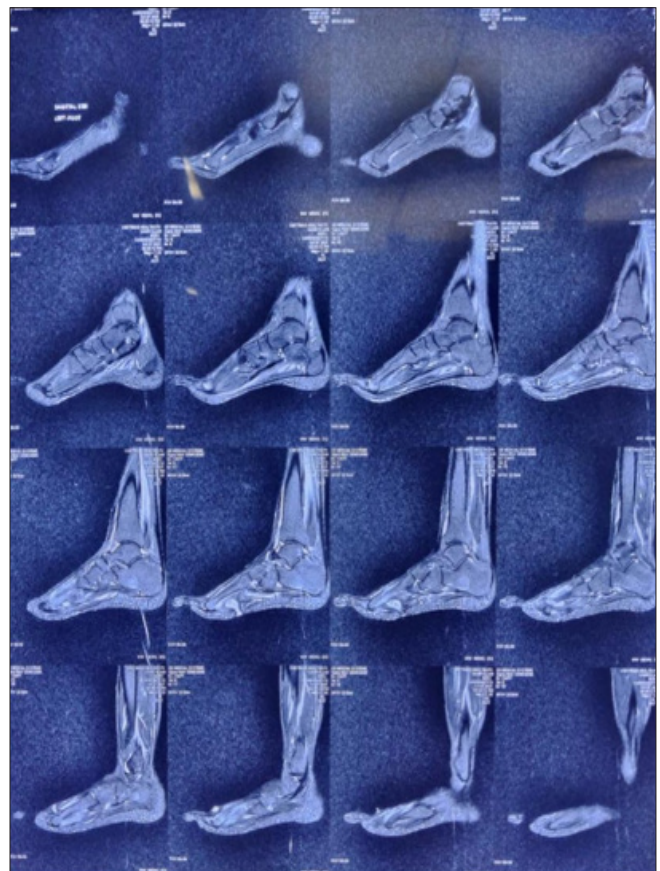


Figure 3. MRI of the Left Foot

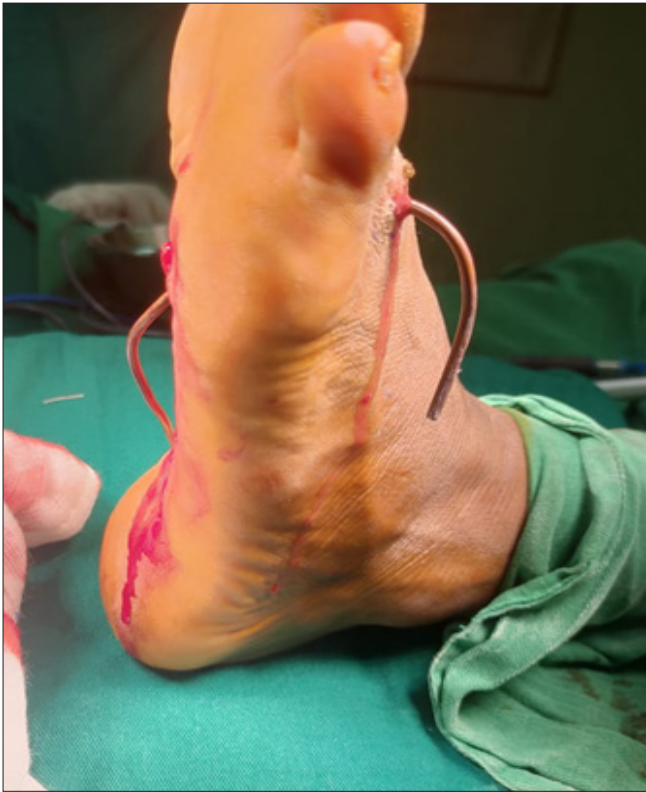

Figure 4. Fistula Probe Inserted into the Left Foot through Dorsal Opening

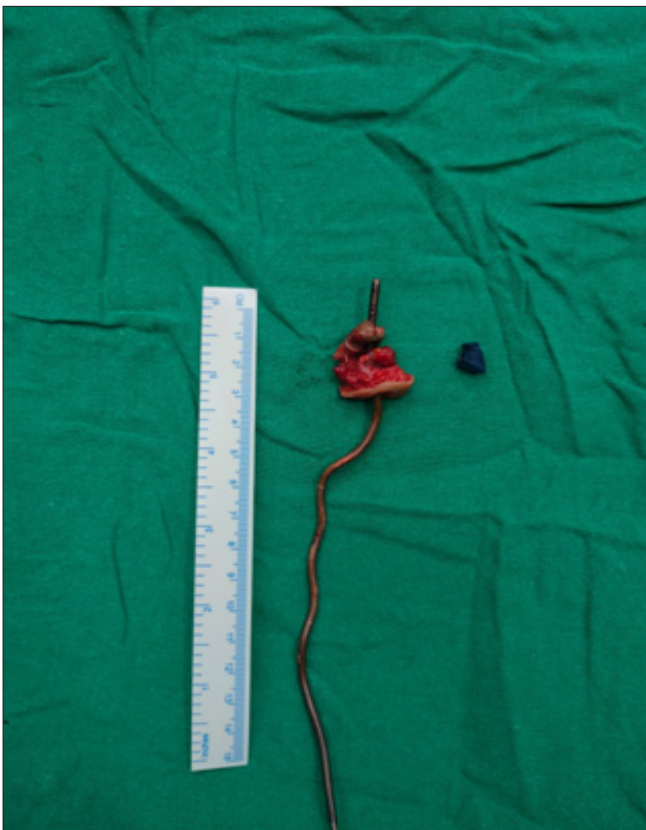


Figure 5. Specimen with Foreign Body (Piece of Rubber Slipper)

Discussion

A fistula is a communicating tract between two epithelial surfaces commonly between a hollow viscus and the skin or between two hollow viscera. The causes of persistent fistula may be a foreign body or necrotic tissue underneath. It can also occur because of insufficient or non-dependent drainage. Fistula can occur due to any faecal fistula or biliary fistula which can occur because of obstruction in lumen. One of the main causes of fistula formation is infections like actinomycetes and tuberculosis. Other causes include radiation exposure and malignancy.

Commonly found foreign bodies in the foot are thorns, plastic, and glass pieces. A retained piece of rubber slipper is very rare.^{1,2} Imaging is very important in the diagnosis of this pathology. Radiological visualisation of the foreign body is required in all cases.

Metal and radiopaque materials are detected using conventional x-rays but these x-rays are not sufficient to visualise radiolucent objects such as wood particles, rubber, and plastics. In our case, the retained foreign body was a piece of rubber slipper. Ultrasound should be the first option for penetrating injuries caused by radiolucent objects.

In the case of detecting a foreign body, plain film radiography is used. It should be the first line of imaging because it helps in detecting most foreign bodies.^{3,5} Besides being quick and cheap, it is low in terms of radiation exposure. For retained organic material, Magnetic Resonance Imaging (MRI) is the most sensitive study.^{6,7} However, due to ferromagnetic streak artefacts and magnetic material being dislodged because of the strong magnetic field, it is ineffective in the case of metallic foreign bodies.

A foreign body along with structures such as vessels, tendons, nerves, and ligaments can be found with imaging modalities like CT. A CT provides a three-dimensional location which helps in finding the surrounding structures.⁸

Initially, it should be managed with wound irrigation and exploration and the foreign body should be removed without delay before it can complicate to cellulitis or abscess or fistula formation, septic arthritis, osteomyelitis, pseudotumour, or necrotising fasciitis.^{9,10} In our case, the foreign body was identified using magnetic resonance imaging and hence it was surgically removed.

Conclusion

A retained foreign body leading to fistula formation is a rare entity and should be identified before it can lead to serious complications. We report this case to emphasise that healthcare professionals should be aware that neglected foreign bodies can lead to various complications and they should be able to diagnose them with adequate imaging modalities.

Source of Funding: None

Conflict of Interest: None

References

1. Kurer MA, Davey C, Khan S, Chintapatla S. Colorectal foreign bodies: a systematic review. *Colorectal Dis.* 2010;12(9):851-61. [PubMed] [Google Scholar]
2. Kelly J. Vesico-vaginal and recto-vaginal fistulae. *JR Soc Med.* 1992;85:257-8. [PubMed] [Google Scholar]
3. Rafique M. Intravesical foreign bodies: review and current management strategies. *Urol J.* 2008;5(4):223-31. [PubMed] [Google Scholar]
4. Anderson MA, Newmeyer WL 3rd, Kilgore ES Jr. Diagnosis and treatment of retained foreign bodies in the hand. *Am J Surg.* 1982;144(1):63-7. [PubMed] [Google Scholar]
5. Graham Jr DD. Ultrasound in the emergency department: detection of wooden foreign bodies in the soft tissues. *J Emerg Med.* 2002;22(1):75-9. [PubMed] [Google Scholar]
6. Rockett MS, Gentile SC, Gudas CJ, Brage ME, Zygmunt KH. The use of ultrasonography for the detection of retained wooden foreign bodies in the foot. *J Foot Ankle Surg.* 1995;34(5):478-84. [PubMed] [Google Scholar]
7. Saul T, Siadecki SD, Rose G, Berkowitz R, Drake AB, Delone N, Avitabile N. Ultrasound for the evaluation of soft tissue foreign bodies before and after the addition of fluid to the surrounding interstitial space in a cadaveric model. *Am J Emerg Med.* 2016;34(9):1779-82. [PubMed] [Google Scholar]
8. Siegel IM. Identification of non-metallic foreign bodies in soft tissue: *Eikenella corrodens* metatarsal osteomyelitis due to a retained toothpick: a case report. *J Bone Joint Surg Am.* 1992;74(9):1408-10. [PubMed] [Google Scholar]
9. Yanay O, Vaughan DJ, Diab M, Brownstein D, Brogan TV. Retained wooden foreign body in a child's thigh complicated by severe necrotizing fasciitis: a case report and discussion of imaging modalities for early diagnosis. *Pediatr Emerg Care.* 2001;17(5):354-5. [PubMed] [Google Scholar]
10. Gulati D, Agarwal A. Wooden foreign body in the forearm - presentation after eight years. *Ulus Travma Acil Cerrahi Derg.* 2010;16(4):373-5. [PubMed] [Google Scholar]