

CASE REPORT

ANTI RABIES VACCINATION IN PRESENCE OF COVID 19 AFFECTED PATIENT ACCIDENTALLY ASSOCIATED WITH HIV INFECTION

Dr Sumit Poddar*, **Dr. Dipankar Mukherjee****, **Ms Rituparna Roy*****

*Senior Critical Care and Anti-rabies Consultant, Kolkata

** Assistant Professor, Department of Plastic Surgery, NRS Medical College, Kolkata.

***M. Pharma (Jadavpur University) Research Scholar, JNU Jaipur

ABSTRACT

The purpose of this case report is to point out for a fixed guideline of Anti Rabies vaccination in presence of SARS-CoV-2 infection and also associated with other Immuno Compromised disease.

CASE HISTORY AND TREATMENT GIVEN

A 46 years old Hindu, male by profession motor car driver A Jadav, residing at present Kolkata presented with severe cough with high temperature along with respiratory distress with a category III unprovoked bite in right forearm by a suspected rabid dog, on October 15, 2020. The dog was killed by the local people. He was coming to meet the doctor for cough and fever.

He was given thorough and adequate wound toilet with detergent soap and water and given a meticulous treatment with administration of local immunoglobulin entirely with vaccination with Purified Vero Cell Rabies Vaccine (PVRV) and injection tetanus toxoid (TT). His body weight was 50 kg and Inj. Twinrab, a novel cocktail rabies monoclonal antibody with 2000 IU entirely locally was infiltrated.

As the patient shows some significant signs and symptoms of covid 19 infection, he was advised for NS/TS for RT-PCR along with HRCT chest, On thorough evaluation from the history, he told that he is a patient with HIV infection and on Retroviral Therapy. His previous CD4 count a month back was slightly near normal.

He was advised admission for close monitoring as well as all the initial investigations were completed within two days. His RT-PCR for SARS-CoV-2 detected positive with an appearance of ground glass opacities in both lungs and high rise in CRP, D-dimer, high ESR with low WBC count were found. CD4 count was also near normal. His oxygen saturation was about 90% for which additional oxygen support was given and Doxycycline, Oral steroids, tab Pirfenex 900 mg TDS, Tab Decmax 4 mg BD for five days and other supportive therapy with retroviral were advised, and a full course of ARV treatment initiated. The initial tests done from NABL accredited lab.

***Corresponding Author:** Dr. Sumit Poddar MBBS, MBA, PhD (Lincoln University), FRSTM & H (UK), MACCP, MIPHA,56H, Beliaghata Main Road, Kolkata – 700010. Email Id: drsumitpoddar@gmail.com . Mobile:- 9830059468, 9836599468

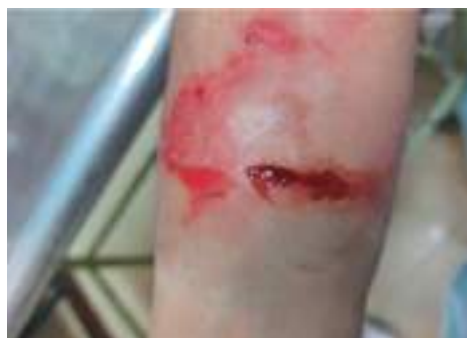Received : 30.10.2020 **Revised :** 02.01.2021

Accepted : 23.01.2021 **Published :** 28.01.2021

The patient recover steadily and RVNA on day 14 and day 18 done and presence of covid antibody were tested on day 18 and day 28.

An additional dose of PVRV were administered on day 21 to further boost up memory cells in order to achieve higher antibody response. The CD4 and CD8 count was more or less same hence retroviral drugs was continued.

As the patient was recovering well he was discharged from the institute after 2 weeks and advised to take ARV treatment (ESSEN Schedule) in follow up clinic as per WHO, NCDC and APCRI guidelines. 1,2,3 The patient was consulted with pulmonologist and HIV specialist.



FOLLOW UP PERIOD AND RESULTS

Patient was keeping well and shows the science of recovery and also some blood test were performed and some investigation were performed which also shows science of gradual recovery

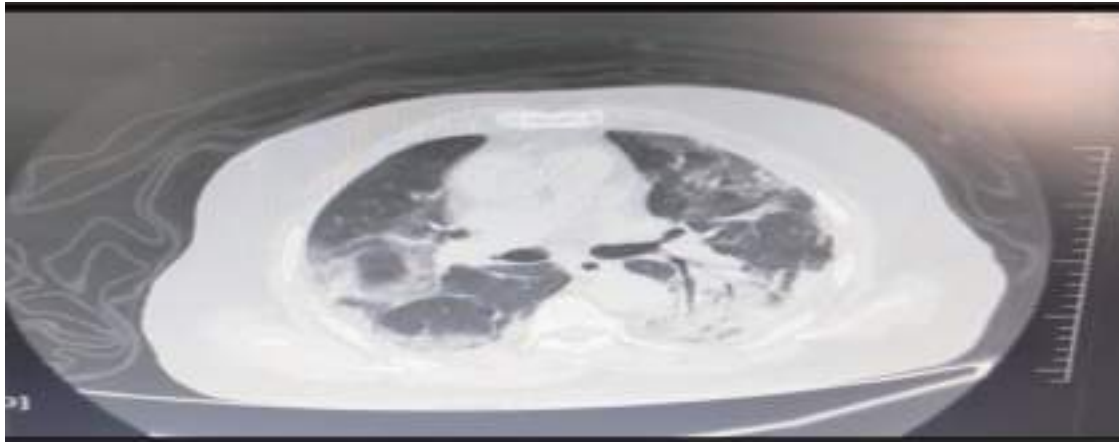
DISCUSSION

The patient was a car driver and a known patient with of HIV infection. Incidentally due to current pandemic situation he also acquired SARS CoV-19 infection and most unfortunately at the same incidence he was bitten badly (Category III) by a suspected rabid dog , and surrounding people killed the dog. Hence the dog could not be observed for assessing the dog is rabid or not.

This type with three components are rare mostly. The main objective is to achieve immunity by activating or stimulating T-cells is important which will save the life of the patient.

Basically the patient is a driver and a history of contact exposure is present. The health in general with his immune system has to be addressed. The underlying cause is most of the serious SARS CoV-19 infected patients at least a five days steroid therapy which is immune-suppressive. In this type of patients where the patient is on immunotherapy or under immune-compromised drugs, the antibody responses after administration of anti-rabies vaccination is not possible to detect all the time. The patient may be saved from Covid 19 infection but may die due to rabies infection. Incidentally he had another component like HIV infection. Hence, meticulous treatment is needed to save the life. A thorough guidelines should be sketched and to be informed in details. Hence, any patient with history of animal bite should stress on thorough and scientific would toilet with detergent soap and water along with associated treatment is a must. The main objective for wound wash is to clean the wound as far as virus free as possible.(assuming near about 50%)

In addition routine checkup of pathological investigations are needed as to monitor the CD4 count which plays the key role in stimulating the T-cells. The specialist concern has also pointed out to continue the retroviral drugs. This patient was put under close observation with continuation of medical and treatment support as there is a possibility of T-cell depletion, which may result in immunological failure.



SUMMARY AND CONCLUSION

A patient with suspected rabid dog category III bite with presence of SARS CoV-19 infection associated with HIV infection reported in the institute on October 15, 2020. He finally received full dose of anti rabies treatment including thorough wound toilet, local infiltration of novel cocktail R-mab's used for dual protection against rabies in a dose of 40 IU/per kg body weight. The objective is to neutralize rabies virus at the site of entry along with administration of full course of PVRV including one additional dose of PVRV in between on day 21 in order to more boosting up of memory cell for attaining immunity in protective level. The patient was also on retroviral therapy as he was also a patient of HIV infection. His CD4 count was also checked and assessed. The patient was also on oral steroid medication for five days which was not much interfered with the treatment as well as antibody production.

Some queries and questions are still unanswered like there is T-cell depletion in presence of HIV infection as well as to ascertain the cell mediated immunity, stimulation of T-cell is needed which will induce a long lasting protection against rabies virus as well as SARS CoV-19 infection. This is a fact that both will produce protective level of antibody from 14 days onwards. The only thing is the presence of HIV infection in this case. But this is of course an exception and never will be found frequently.

In this case the patient was given additionally the HIV retroviral drug and stressed on repeated investigations.

Lastly for the future, there are some burning questions like can covid 19 vaccine recipient's be given other vaccines at the same visit or not. In fact there is no sufficient specific data on safety, efficacy, immunogenicity, span of immunity of mRNA covid 19 vaccine with other vaccines still now. CDC recommends to take other vaccines with 14 days interval.⁴

Administration of Inj. Tetanus Toxoid should be given as a part of any wound management. In case of ARV is also the same. A thorough study in this regard may clear the confusions.

Recently an article published on CoravaxTM, a rabies virus based covid 19 vaccine which induces high level of neutralizing antibodies against SARS-CoV infection were introduced the SARS-CoV-2 S1 protein in to the alternated RABV vector induces potent virus neutralization antibody at much higher level seen in sera of convalescent patient. It may be a milestone against covid-19 like infection.⁵

The main objective of this case report is to highlight the presence of other diseases found along with, and proper treatment after animal bite exposure for prevention of rabies.

ACKNOWLEDGEMENT

My Sincere thanks to Dr. Asit Deb MD, Dr. Snehamay Chaudhury MD, Dr. Saikat Nag MD Pulmonologist, Mr. Jiten Singh for their continuous help in preparing the article.

I acknowledge Mrs. Dipali Poddar, Director Institute of Animal Bite Management and H.P. Poddar Memorial Clinic and Nursing Home for allowing us to use the Treatment Records.

REFERENCES

1. *WHO Expert Consultation on Rabies. Third Report, Technical Report Series 1012.* World Health Organization, Geneva, 2018
2. *National Rabies Control Programme. National guidelines for rabies prophylaxis, National Centre for Diseases Control, Ministry of Health and Family Welfare, New Delhi, India. 2015. p. 7-12*
3. *Association for Prevention and Control of Rabies in India (APCRI).* www.apcri.org
4. <https://www.cdc.gov/vaccines/covid-19/hcp/faq.html>. (Assessed on 03 February 2021)
5. Kurup, D., Wirblich, C., Ramage, H. et al. Rabies virus-based COVID-19 vaccine CORAVAX™ induces high levels of neutralizing antibodies against SARS-CoV-2. *npj Vaccines* 5, 98 (2020). <https://doi.org/10.1038/s41541-020-00248-6>